



**Patient Name:** MD. MOSTAFA KAMAL  
**Registration No:** UHID-2132330 **Age/Sex:** 32 Yrs/M  
**Diagnosis:**

**Ref By:** DR M K GOENKA  
**Date:** 02-05-2023 02:55:00 PM  
**Procedure:** UGI ENDOSCOPY

**ESOPHAGO-GASTRO-DUODENOSCOPY REPORT**

Preparation used : None  
Medication : Propofol  
Informed consent : Yes  
(VP/A/P)

**ESOPHAGUS**

Mucosa is smooth and pink with no ulcer or erosion. No stricture, polyp or tumor seen. There is no evidence of esophageal varix. Gastro-esophageal junction is located at 37 cm. from incisor teeth. No evidence of hiatus hernia.

**STOMACH**

Fundus, body and antrum examined. No food residue, foreign body or blood seen. Few erosions seen in fundus. A small (0.5cm in size) healing ulcer with clean base in prepyloric ulcer. There is no suggestion of gastric varix. Stomach shows no polyp or tumor.

**DUODENUM**

First (D1) & second part (D2) examined. No blood in the lumen. There is no suggestion of ulcers, erosions, diverticulum or duodenal scarring. No nodularity, tumor or polyp seen. Mucosal folds in D2 are normal at endoscopy.

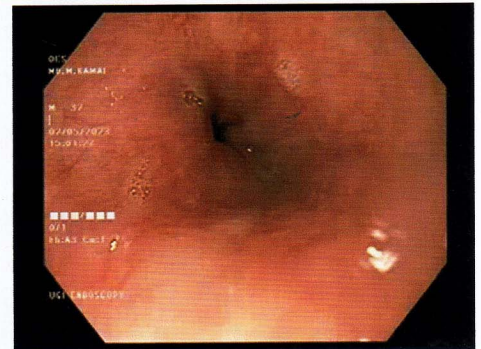
**SAMPLE TAKEN**

Biopsy taken for RUT: Negative

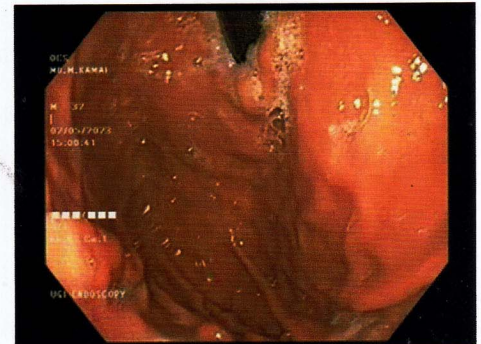
**IMPRESSION**

**GASTRIC ULCER WITH EROSIONS**

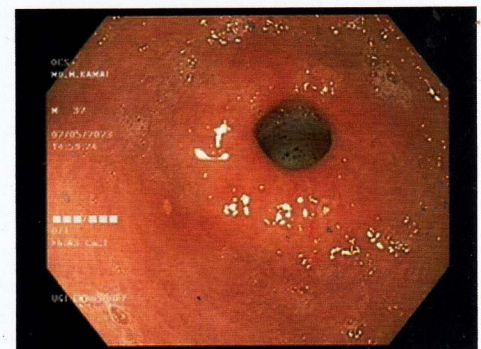
**\*PROCEDURE WAS UNEVENTFUL**



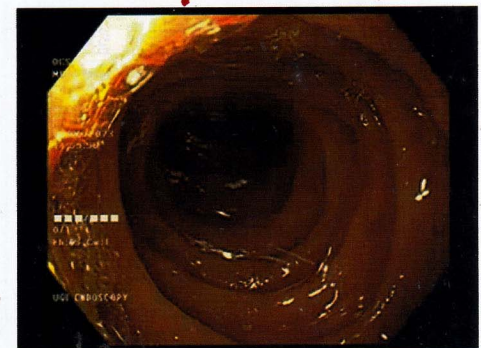
**ESOPHAGUS**



**FUNDUS**



**ANTRUM**



**DUODENUM (D2)**

Dr M K Goenka Dr N Sonthalia Dr I Tiwari Dr S Das  
Dr A Tiwari Dr S Banerjee Dr V Patil