



গণপ্রজাতন্ত্রী বাংলাদেশ সরকার
Government of the People's Republic of Bangladesh
জাতীয় পরিচয়পত্র / National ID Card

29 Jun 1967



নাম

রনজিৎ কুমার হালদার

Name

RANJIT KUMAR HALDER

পিতা

বিজয় কুমার হালদার

মাতা

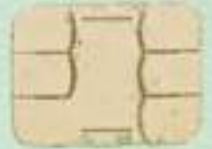
অঞ্জলী রানী হালদার

Date of Birth 29 Jun 1967

NID No.

237 150 1038

রনজিৎ





গণপ্রজাতন্ত্রী বাংলাদেশ সরকার
Government of the People's Republic of Bangladesh
জাতীয় পরিচয়পত্র / National ID Card



নাম

রথীন বর

Name

RATHEN BOR

পিতা

স্বপন বর

মাতা

রেনু বর

Date of Birth 04 Jun 1996

NID No.

865 218 8080

রথীন





Lab ID	23092369	SRNGIH Reg no	181/337		
Patient Name:	Mr. Ranjit Kumar	Age:	56 Yrs	Sex:	M
Refd. By:	OPD	Specimen:	Tissue from caecum and ileocecal valve		
Clinical Details:					
Specimen received on	18/09/2023	Reported on:	23/09/2023		

Thanks for referring the patient

HISTOPATHOLOGY REPORT

Gross description:

Specimen received in formalin in a container from OPD with name, age, sex, date, reg no, hospital name and sample name:
Specimen consists of multiple fragmented grayish white pieces of soft tissue totally measure 0.8X0.6X0.3 cm.


Section code:

A1: Multiple pieces entirely embedded in one block.

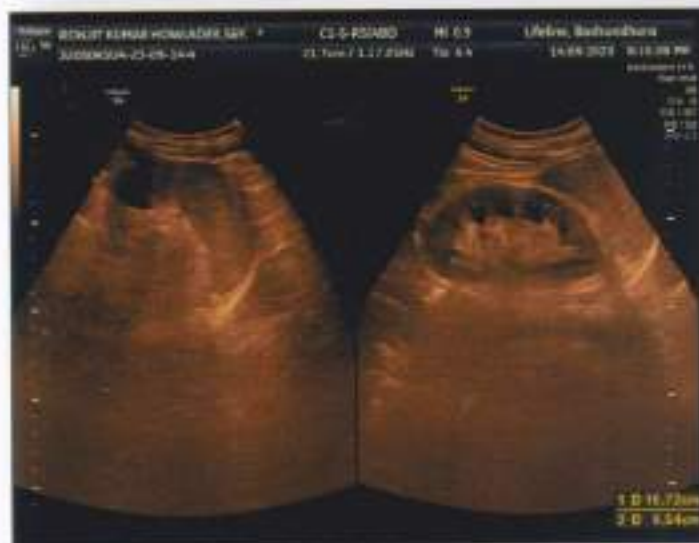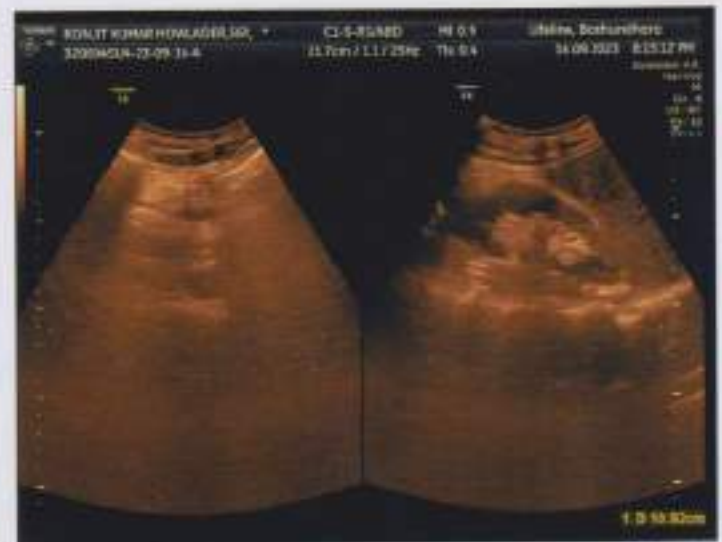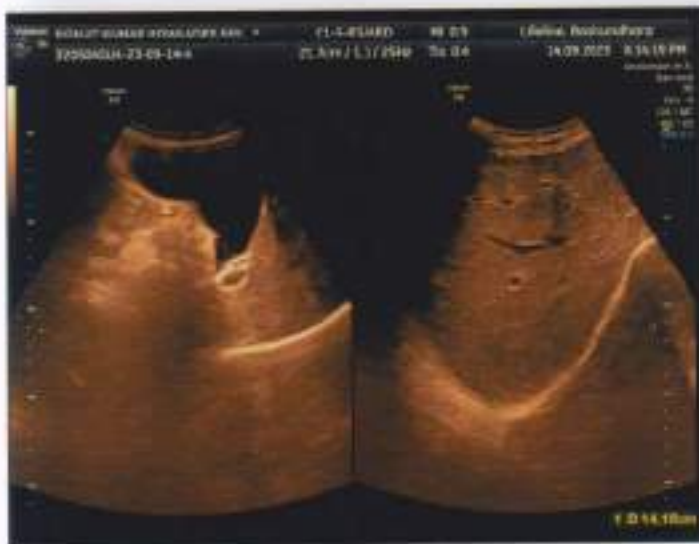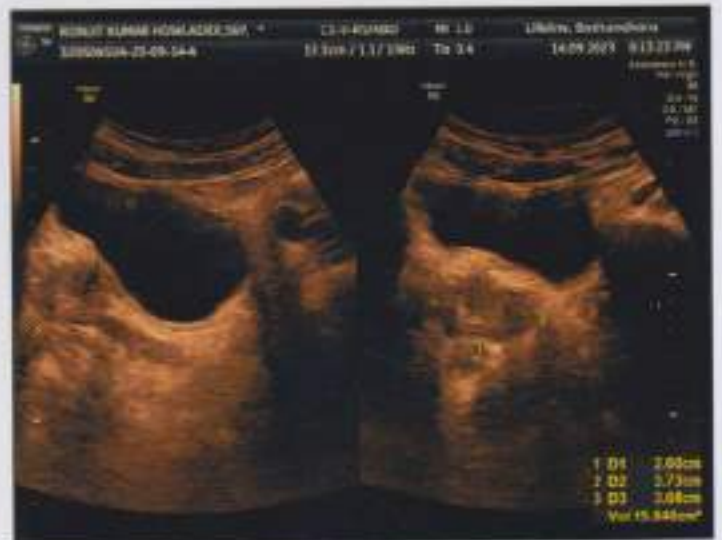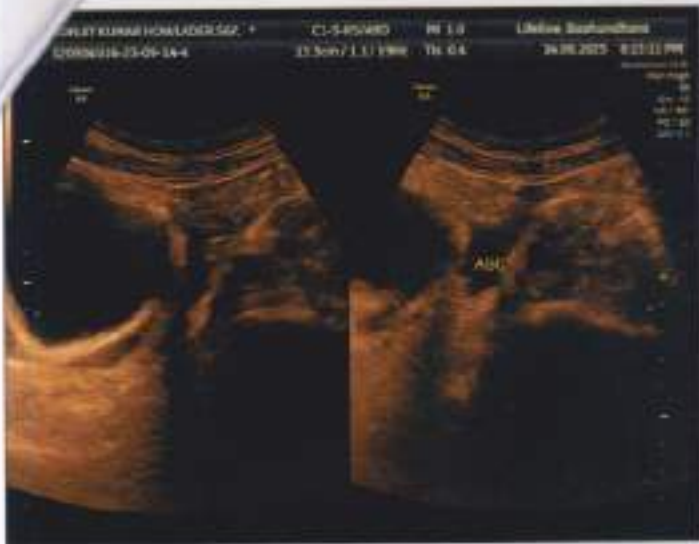Microscopic description/comment:

Sections show colonic mucosae. These reveal an adenocarcinoma. The tumor is moderately differentiated.

Diagnosis: Tissue from caecum and ileocecal valve; colonoscopic biopsy: Adenocarcinoma, moderately differentiated.


23/9/23
Dr. Farhana Yusuf
MBBS, MD (Pathology)
Assistant Professor
Department of Histopathology


23/09/2023
Dr. Fahmida Akter Rima
MBBS, MD (Pathology)
Assistant Professor
Department of Histopathology





Invoice No : L2309090814	Invoice Date : 14/09/2023	Delivery Date : 14/09/2023	Report No. :
Patient Name : MR. RONJIT KUMAR HOWLADER	Age : 56Y	Gender : M	
Ref. Doctor : ASST.PROF.DR. ABUL BASHER BISWAS, MD(MEDICINE),CO (GASTRO)			
Test Name :	USG of WVA		

LIVER: Normal in size (14.1 cm) and shape with uniform echotexture. No focal lesion is seen. Intrahepatic vessels are well visualized.

GALL BLADDER: Is normal in size. Walls are not thickened. Both CBD & Intrahepatic biliary trees are not dilated.

PANCREAS: Normal in size and uniform in echo texture.

SPLEEN: Not enlarged (10.7 cm) and uniform in echotexture.

KIDNEY: Both the kidneys are normal in size, shape and position. Bipolar length of right and left kidney is about 10.9 cm and 10.7 cm respectively. Cortex and medulla can be defined. Pelvicalyceal systems are not dilated. No renal calculus could be seen.

URINARY BLADDER: Urinary bladder is well filled. Wall thickness is within normal limit. No intravesical lesion is seen.

PROSTATE: Prostate is normal in size (Vol: 15.6 cc) and uniform in echotexture.

IMPRESSION: Trace ascites.


14.09.23

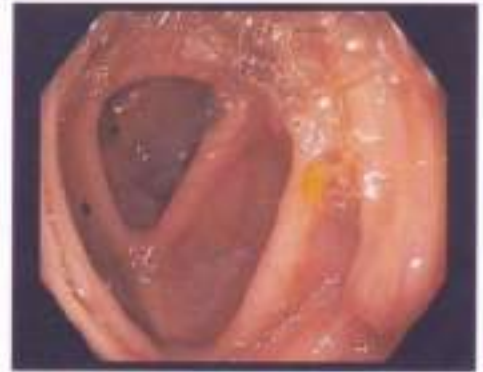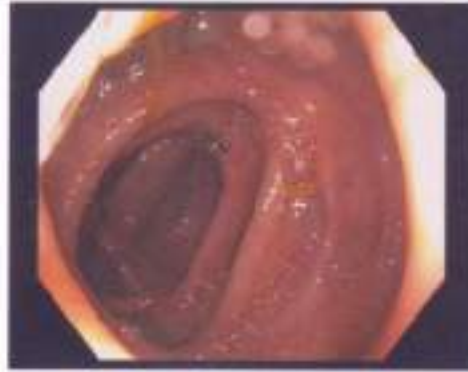
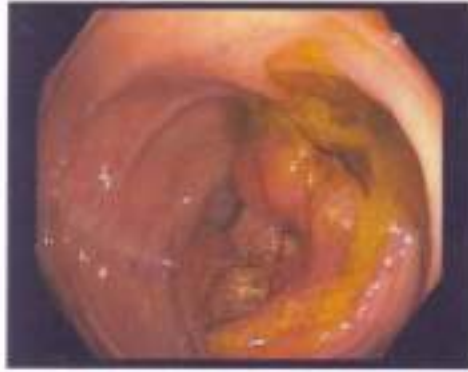DR. MD. TOWFIQ AHMED

MBS, BCS (HEALTH) CMU.
DIPLOMA IN MEDICAL ULTRASOUND
TRAINED IN NUCLEAR MED & COLOR DOPPLER
INM&U(BSMMU CAMPUS), WFUMB
P&T (RADIOLOGY AND IMAGING)
LIFELINE CONSULTATION & DIAGNOSTIC LTD.



Identity No.	181/331	Visit Date	18 September, 2023
Patient Name	Ranjit Kumar	Age / Sex	56 / Male
History	H/O, Weight loss	Instrument	Olympus 150
Referrer	MGU-VIOLET-OPD	Bed	OPD.W-603,B-46

ENDOSCOPIC PROCEDURE REPORT



Procedure : COLONOSCOPY

Indication : Abdominal pain.

Medication : Inj Fentanyl 25, Inj Midazolam 2mg

FINDINGS :

Boston Bowel preparation score: 6

- **Seen Up To Caecum-**
- **Perianal area:** Normal.
- **Anal canal :**Normal.
- **Rectum ,colon and terminal ileum:** There is ulceronodular lesion seen at the caecal region. Scope could not be negotiated to the caecal pole and ileal intubation was not possible. Mucosa, vascular pattern & lumen of rectum and rest of the colon appeared normal.

- **Biopsy:-** Taken from the ulcers and sent for histopathology and Gene Xpert.

COMMENTS : Colonic ulcers.

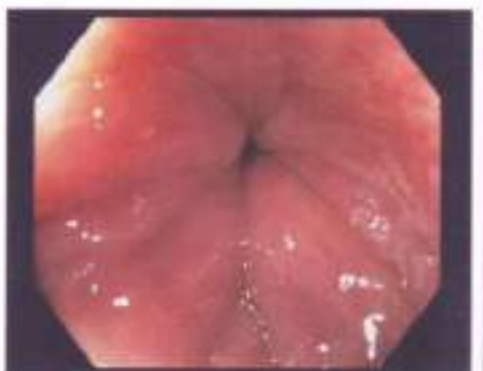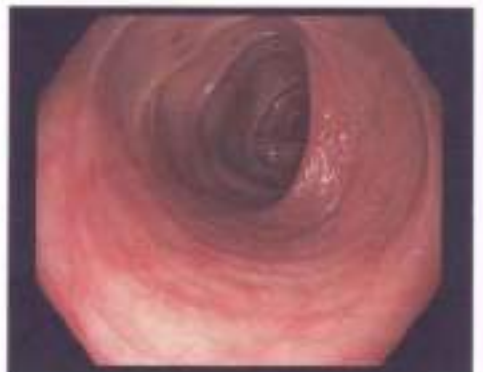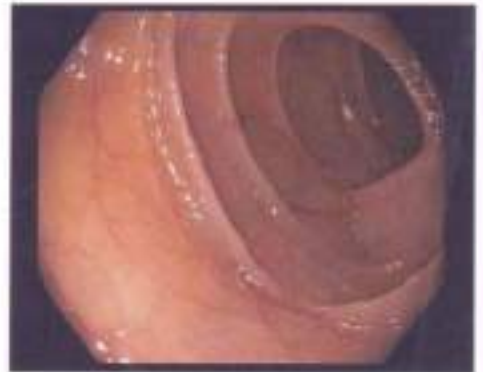D/D: Tuberculosis/Crohn's disease/ Lymphoma/ Carcinoma.


Dr. Rajib Dutta

MBBS, MD-Gastroenterology

MO

SRNGIH





X-RAY REPORT

Invoice No : 12410150705 Invoice Date: 18/10/2024 01:55 PM
MRN : H2403051997 Report No:
Patient Name: MR. RANJIT HALDER
Age / Gender: 57Y 3M 21D / Male
Ref. Doctor : DR. N.M. NAZMUL KABIR PRODHAN MBBS, DA DU, Fellowship in Palliative Medicine IPM, India,
SENIOR CONSULTANT, ASSOCIATE PROF. & HEAD, PCU

Delivery Date: 18/10/2024
Report Status: FINALIZED
Admission No: A2410026531
Bed No: 525/PCU-M-3

Test name : ABDOMEN IN E/P

ABDOMEN

No crescent gas shadow seen under the domes of diaphragm.

Multiple air fluid levels and distended bowel loops are seen in central part of abdomen.

No radio opaque shadow suggesting calculous seen.

No calcific shadow seen.

No bony lesion seen.

Impression: Suggestive of small intestinal obstruction.

Prepared By
Ms. Shirin Akhter

**PROF. DR. SHAIKH SHOFIUR
RAHMAN**

MBBS, M.Phil(Radiology and Imaging)
Professor & Head
Department of Radiology & Imaging
Delta Medical College & Hospital



X-RAY REPORT



Invoice No : 12410150705 Invoice Date : 18/10/2024 01:55 PM Delivery Date : 18/10/2024
MRN : H2403051997 Report No: Report Status : FINALIZED
Patient Name : MR. RANJIT HALDER Admission No. : A2410026531
Age / Gender : 57Y 3M 21D / Male Bed No : 525/PCU-M-3
Ref. Doctor : DR. N.M. NAZMUL KABIR PRODHAN MBBS, DA-DU, Fellowship in Palliative Medicine IPM, India,
SENIOR CONSULTANT, ASSOCIATE PROF. & HEAD, PCU

Test name : ABDOMEN IN E/P

ABDOMEN

No crescent gas shadow seen under the domes of diaphragm.

Multiple air fluid levels and distended bowel loops are seen in central part of abdomen.

No radio opaque shadow suggesting calculous seen.

No calcific shadow seen.

No bony lesion seen.

Impression: Suggestive of small intestinal obstruction.

Prepared By :
Ms. Shirin Akhter

PROF. DR. SHAIKH SHOFIUR
RAHMAN

MBBS, M.Phil(Radiology and imaging)
Professor & head
Department of Radiology & Imaging
Delta Medical College & Hospital

Printed by: SHIRIN Printed Date : 20/10/2024 09:00 AM

Page 1 of 1

Software By : Mysoft Limited



শেখ রাসেল জাতীয় গ্যাস্ট্রোলিভার ইনস্টিটিউট ও হাসপাতাল
Sheikh Russel National Gastroenterology Institute & Hospital
Mohakhali Dhaka-1212 Bangladesh



ELECTROCARDIOGRAPHY (ECG) REPORT

ECG No: ১৯৭০১৫০৭০১ Reg. No: ২৭১০০২৬৫৩১ Date: _____
Patient's Name: MN-Ranjit Halder Age: 57y Sex: M/F
Ref by: Prof/Dr. N. M. Nazmul Kabir prodkan
Designation: _____ Dept: _____
Cabin No / Bed No: M/3 Ward / OPD: PCR - m/3
Hospital/Clinic: DHL



Delta Hospital Limited

26/2, Principal Abul Kashem (Former Darussalam) Road, Mirpur-1, Dhaka-1216

Tel : 48037064, 48039084, 58050661, 58050663, 58053461

Website : www.delta-hospital.com, E-mail : delta@delta-hospital.com

23/9/23

Dr. Farhana Yusuf
MBBS, MD (Pathology)
Assistant Professor
Department of Histopathology

25/

Dr. Fahmida Akter Fima
MBBS, MD (Pathology)
Assistant Professor
Department of Histopathology



ECG REPORT

Description: bpm

Rhythm:

Rate:

PR Interval:

P Wave:

ST Segment:

QRS Complex

Morphology:

QT Interval:

R Wave:

QTc Interval:

S Wave:

T Wave:

Pathological Q:

Voltage:

U Wave:

Duration/Width:

Other (s):

Axis:

Comment (S):

Left Anterior Hemiblock
 Poor R wave progression

Advice/Recommendation (S):

Adv. Echo 2D in chest leads

Dr. S. Chakrabarty
 MBBS (DNO), MD (Cardiology), FSC
 BMDC Reg. No: A-32276
 Senior Consultant, Dept. of Cardiology
 Delta Hospital Limited, Dhaka

Cardiologist


23/9/23
 Dr. Farhana Faruq
 MBBS, MD (Pathology)
 Assistant Professor
 Department of Histopathology

MBBS, MD (Pathology)
 Assistant Professor
 Department of Histopathology

ডেল্টা হাসপাতাল লিমিটেড
Delta Hospital Limited



IMMUNOLOGICAL TEST REPORT



Report No : 12410150792 Invoice Date : 18/10/24 09:15:46 PM Delivery Date : 19/10/24
Patient Name : MR. RANJIT HALDER Age : 57Y 3M 19D Report No : 12410179709
Gender : Male
Requested By : DR. N.M. NAZMUL KABIR PRODHAN MBBS, DA (DU), Fellowship in Palliative Medicine (IPM, India),
SENIOR CONSULTANT, ASSOCIATE PROF. & HEAD, PCU
Accession No : A2410026531 Ward : 4TH FLOOR PCU MAI Bed : 525/PCU-M-3

Specimen : SERUM
Dengue NS1 Ag
Lab No : 12418204726
Coll Time : 18/10/24 08:28 pm
Lab Receive Time: 18/10/24 09:28 pm

Test	Result	Method
Dengue NS1 Ag	Negative ✓	ICT

Requested by:
Subash Kumar Sarkar
Senior Medical Technologist
Delta Hospital Ltd

Verified by
Md. Marjorat Momenin
Senior Medical Technologist
Delta Hospital Ltd

Medical Officer
Blood Bank & Pathology
Delta Hospital Limited

Date : SUBASH on 18/10/2024 09:14:02 PM



URINE EXAMINATION REPORT



12410158705 Invoice Date : 18/10/24 Delivery Date : 18/10/24 Report No : 12410179775
 MR. RANJIT HALDER Age : 57Y 3M 19D Gender : Male
 DR. N.M. NAZMUL KABIR PRODHAN MBBS, DA (DU), Fellowship in Palliative Medicine (IPM, India),
 SENIOR CONSULTANT, ASSOCIATE PROF. & HEAD, PCU
 12410026531 Ward : 4TH FLOOR PCU MAI Bed : 525/PCU-M-3
 LAB. No : 12410204615
 Receive Time : 18/10/24 03:47 pm

	Result	Test Name	Result
Volume	20 ml		
Container	Straw		
Appearance	Hazy		
Color	Nil		
Specific Gravity	N/D		
Chemical Examination			
Color	Acidic		
Reaction of Phosphate	Nil		
	(+)		
	(++)		
Microscopic Examination			
Red Cell	0-2 /HPF		
White Cell	↑ 2-4 /HPF		
Epithelial Cell	Nil		
Crystals	(+)		
Bilirubin Cast			

Verified by Senior Medical Technologist

Medical Officer
 Blood Bank & Pathology
 Delta Hospital Limited
 Signature



HAEMATOLOGY REPORT



MR. RAJIT HALDER
DR. N. M. NAZMUL KABIR PRODHAN MBBS, DA (DU), Fellowship in Palliative Medicine (IPM, India),
SENIOR CONSULTANT, ASSOCIATE PROF. & HEAD, PCU
Ward : 4TH FLOOR PCU MALE AC WARD BLOCK-A Bed : 525/PCU-M-3

Invoice Date : 18/10/24 01:55:36 PM Delivery Date : 18/10/24 Report No : 12410179684
Age : 57Y 3M 19D Gender : Male

Call Time : 18/10/24 03:39 pm Lab Receive Time: 18/10/24 03:39 pm

Estimations were carried out by automated analyzer Sysmex XN 1000, Vision C and Checked manually.

	Result	Unit	Reference Value
Hemoglobin	10.6	g/dL	Adult: Men: 15.0±2.0, Women: 13.5±1.5 At birth: 13.5, 3 Days: 14.5 - 22.5, 1Month: 11-17 2-6 Months: 9.5-13.5, 2-6 Years: 11-14, 6-12 Years: 11.5-15.5
Hematocrit	32.4	%	36 - 50
MCV (Mean Corpuscular Volume)	45	mm in 1st hour	Men: 0-10, Women: 0-20
MCH (Mean Corpuscular Hemoglobin)	4.14	10 ¹² /L	Men: 4.5-5.5, Women: 3.8-4.8
MCHC (Mean Corpuscular Hemoglobin Concentration)	0.0	%	0.0
RDW (Red Cell Distribution Width)	78.3	fL	83 - 101
Platelet Count	25.95	10 ⁹ /L	27.0-32.0 32.0 - 36.0 39.0 - 46.0 11.60 - 14.80 Adult: 4-10, (Upto 1 Year): 6 - 16, (2-6 Year): 5-15, (6-12 Year): 5-13
Neutrophil Count	94.2	%	40 - 60
Lymphocyte Count	4.1	%	20 - 40
Monocyte Count	1.5	%	02-10
Eosinophil Count	0.1	%	01-06
Basophil Count	0.1	%	<01
Neutrophil	24.43	10 ⁹ /L	2.00 - 7.00
Lymphocyte	1.07	10 ⁹ /L	1.00 - 3.00
Monocyte	0.39	10 ⁹ /L	0.20 - 1.00
Eosinophil	0.03	10 ⁹ /L	0.02 - 0.50
Basophil	0.03	10 ⁹ /L	0.02 - 0.10
Platelet Count	↑ 658	10 ⁹ /L	Adult: 150 - 450, Neonate: 100 - 400
MPV (Mean Platelet Volume)	8.0	fL	7.0 - 11.0

By: Faruk
Senior Medical Technologist
Delta Hospital Ltd.

Verified by: [Signature]
Senior Medical Technologist

DR. MAMUNUR RAHMAN
MBBS, MPH, MCPS (Lab Medicine)
Consultant, Laboratory Medicine
BM&DC Reg. No: A-18923
Delta Hospital Ltd., Dhaka

Date : 18/10/2024 04:12:30 PM



BIOCHEMICAL TEST REPORT



12410150795 Invoice Date : 18/10/24 01:55:36 PM Delivery Date : 18/10/24 Report No : 12410179698
 MR. RANJIT HALDER Age : 57Y 3M 19D Gender : Male
 DR. N.M. NAZMUL KABIR PRODHAN MBBS, DA (DU), Fellowship in Palliative Medicine (IPM, India),
 SENIOR CONSULTANT, ASSOCIATE PROF. & HEAD, PCU
 Patient No : ASM10026531 Ward : 4TH FLOOR PCU MALE AC WARD BLOCK-A Bed : 525/PCU-M-3

Tests: S. Electrolyte, S. Creatinine, Albumin, T. Calcium
 Call Time : 18/10/24 09:39 am Lab Receive Time: 18/10/24 03:38 am

Estimations have been carried out by Cobas C311,

	Result	Unit	Reference Value
S. Sodium	↓ 131.00	mmol/L	135.0 - 145.0
S. Potassium	↓ 3.40	mmol/L	3.5 - 5.1 (Serum) 3.4 - 4.5 (Plasma)
S. Creatinine	89.00	mmol/L	68.0 - 106.0
T. Calcium	27.00	mmol/L	21.0-31.0 (Adult) 17.0-24.0 (Child)
S. Albumin	18.40	mmol/L	10.0 - 20.0
S. Urea Nitrogen	✓ 0.98	mg/dL	0.12 - 0.38 (Infant), 0.24 - 0.74 (Child), Adult: 0.72 - 1.18 (Men), 0.55 - 1.02 (Women)
S. Glucose	↓ 2.94	g/dl	3.5 - 6.2 (Adult), 2.8 - 4.4 (newborn)
S. Hemoglobin	✓ 9.10	mg/dl	Adult: 8.8-10.6, Child: 7.8-10.8

Order by:
Subash Kumar Sarkar
Senior Medical Technologist
Delta Hospital Ltd

Verified by: *[Signature]*
Mr. Subash Kumar Sarkar
Senior Medical Technologist
Delta Hospital Ltd

[Signature]
Medical Officer
Blood Bank & Pathology
Delta Hospital Limited

Printed & Date: SUBASH on 18/10/2024 04:46:23 PM

Delta Hospital Limited

Shustho Jibon, Shundor Prithibee
26/2, Principal Abul Kashem Road,

Phone- 0241002124, 0241002125, 0241002126 Mobile: 01720-23

Admission Report

Office Copy



2403051997



AN : A2410026531

Name : MR. RANJIT HALDER

Age : 57Y 3M 19D

Gender : Male

Name :

Name :

Name : S/O- BIJOY KRISHNO HALDER

No. : 01715530417

Address : SATPAR, DO.SADAR GOPALGONJ

Phone :

No. : 017:5530417

Relation :

By :

Physician : DR. N.M. NAZMUL KABIR PRODHAN

MBBS, DA (DU), Fellowship in Palliative Medicine (IPM, India) . SENIC

Admission : 18/10/2024 12:49 PM Department : PALLIATIVE CARE UNIT (I

Address : 4TH FLOOR PCU MALE AC Bed Name : 525/PCU-M-3

Medical Service :

Item Name

Bed Charge

Amount

3,500

Thousand Five Hundred Taka Only.

Total : 3,500

Pay No.

4100000051313

Payment Mode

Cash

Amount

6,000

Thousand Taka Only.

Total 6,000

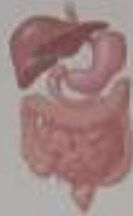Physician/Contact Person

Software By: MySoft

Signature

ডাঃ প্রবীর কুমার ব্যানার্জী

এম.বি.বি.এস. (ডিএফসি) বি.সি.এস. (স্বাস্থ্য)
এফসিপিএস (মেডিসিন) এমডি (গ্যাস্ট্রো)
সহকারী অধ্যাপক, প্যাথোলজি
মেডিসিন, সিজার এবং পরিপাকতন্ত্র বিশেষজ্ঞ
শেখ সায়েদা বাতুন বেভিকেল কলেজ, গোপালগঞ্জ।
রিএমভিসি রেজি: নং: এ-০২৪০৯



Dr. Probir Kumar Banerjee

MBBS (DMC), BCS (Health)
FCPS (Med), MD (Gastro)
Assistant Professor, Gastroenterology
Medicine, Liver & Gastro Specialist
Sheikh Sayeda Khatun Medical College, Gopalganj
BMDC Reg. No. A-32409
E-mail: probirk51@gmail.com

RANAJIT HALDER, P-2LSB7577J

57Y

Oct 16, 2024 5:43 PM

- H/O LOOSE STOOL FOLLOWED BY Constipation
- Abdominal pain

History

Medical

- Hypertension (HTN): No
- Diabetes Mellitus (DM): No
- CA COLON OPERATED

Findings

- BP: 120 / 80mmHg
- COLOSTOMY BAG PRESENT

Rx

1. FLOXABID TAB 500mg

১-০-১

৭ দিন ভরা পেটে

2. MARLOX PLUS SYRUP (400mg+20mg)/5ml

২-২-২ চামচ

১৪ দিন ভরা পেটে

3. ROLAC INJ 30mg

১ গ্রাম্পুল গভীর অংশে

৩ দিনে ২ বার ৩ দিন

4. EXIUM CAP 40mg

১-০-১

২ মাস খাওয়ার আধ ঘণ্টা আগে

পরামর্শ

1. অপর্যায় ঔষধ চলবে।

Signature

Diagnostic Center