



ন্যাশনাল হার্ট ফাউন্ডেশন হাসপাতাল অ্যান্ড রিসার্চ ইনস্টিটিউট
NATIONAL HEART FOUNDATION HOSPITAL & RESEARCH INSTITUTE

OPD Ticket

ROOM NO: ROOM - C

Registration Date: 10-Sep-2024 11:39 am

Tiket No. : 104-1612/40381-24

TOKEN: 104



PID No. : 621366-21

Specification: General

Patient Type Follow Up

Name : Sheikh Abdul Alim

Age : 60Y-0M-0D Sex : Male

Address : C-1/12, Sec-13, Kafrul Dhaka

Marital Status : Married

Mobile :

Doctor : Dr. Kamrul Hasan Jewel

Received Amount Tk. 50.00

NB: Sold Ticket including payments is not refundable.

Prescription (Only for Doctor's Use)

ECG!
~~ECG~~
Pt come for
chk UP
excrampy muscles
pain
O/E
TSP: 120/80mmHg
Pulse 80/min
Tunio
HLLI/AN

AAvi
ECG

DH
ADIT

Rx:
Tab. Ecosprin PLUS - 100 - 100 - 100
Tab. Rosuva (10mg) 2000 - 100 (100)
Tab. tenobis (25mg) 2000 - 100
Tab. Nifedipine SR (20mg) 2000 - 100
Tab. Metoprolol MR (25mg) 2000 - 100
Tab. Amlodipine (5mg) 2000 - 100
Cap. Dabigatran (150mg) 2000 - 100
Tab. Folicine (5mg) 2000 - 100
Tab. Neurobest - 2000 - 2000
Tab. Limbix - 2000 - 2000

[Signature]

Dr. Kamrul Hasan Jewel



ন্যাশনাল হার্ট ফাউন্ডেশন হাসপাতাল অ্যান্ড রিসার্চ ইনস্টিটিউট
NATIONAL HEART FOUNDATION HOSPITAL & RESEARCH INSTITUTE

OPD Ticket

ROOM NO: ROOM - C

Registration Date: 11-Sep-2021 10:08 am

Tiket No. : 77-1837/33540-21

TOKEN: 077



PID No. : 621366-21

Specification: General

Patient Type New

Name : Sheikh Abdul Alim

Age : 57y

Sex : Male

Address : C-1/12, Sec-13, Kafrul Dhaka

Marital Status : Married

Mobile :

Doctor : Dr. Wahid Sadique Anik

Received Amount Tk. 50.00

NB: Sold Ticket including payments is not refundable.

Prescription (Only for Doctor's Use)

<p>CC:</p> <ul style="list-style-type: none"> • Left sided chest discomfort for 7 days. • Exertional discomfort. <p>PR: 84/min BP: 100/90</p> <p>ECG</p> <p>Top-2</p>	<p>DM^o CMK^o HTN^o CA^o</p> <p>Adm: Admission - Refused</p> <p>Rx on request:-</p> <ul style="list-style-type: none"> • Tab: Ecosprin plus 0+1+0 (as req) • Tab: Anzitas 20 0+0+1 • Tab: Nitrogina 25 1+0+1 • Tab: Acelic 20 0+0+1 • Tab: metaxol 25 1+0+1 • Tab: Metacard MR 30 1+0+1 • Cap: Dexilend 30 1+0+1
---	--

NITROSOL SPRAY
যদি ব্যথা হলে জিহ্বায় দিতে
১ বা দুই পাক দিবেন।

Dr. Wahid Sadique Anik

Powered By: NHF&RI IT

Service given by:

Tania Akter

11-Sep-21 10:08:30AM

PLOT NO-7/2, SECTION-2, MIRPUR, DHAKA-1216, BANGLADESH.

Phone: 58054708-12, Fax: 48039237, Facebook: www.facebook.com/bangladesh.heartfoundation

www.nhf.org.bd E-mail : nhfadmin@agni.com, admin@nhf.org.bd

OPD Ticket

ROOM NO: ROOM - B

Registration Date: 06-Mar-2022 10:06 am

Tiket No. : 53-741/9816-22

TOKEN: 053



PID No. : 621366-21

Specification: General

Patient Type Follow Up

Name : Sheikh Abdul Alim

Age : 57y

Sex : Male

Address : C-1/12, Sec-13, Kafrul Dhaka

Marital Status : Married

Mobile :

Doctor : Dr. Avimanyu Banik Rohan

Received Amount Tk. 50.00

NB: Sold Ticket including payments is not refundable.

Prescription (Only for Doctor's Use)

CLP:-
Chest pain on exertion 6 months

H/W (H) DM (D) smoker (S)

Rx: *[Handwritten medical notes]*

[Handwritten signature]
06/03/22

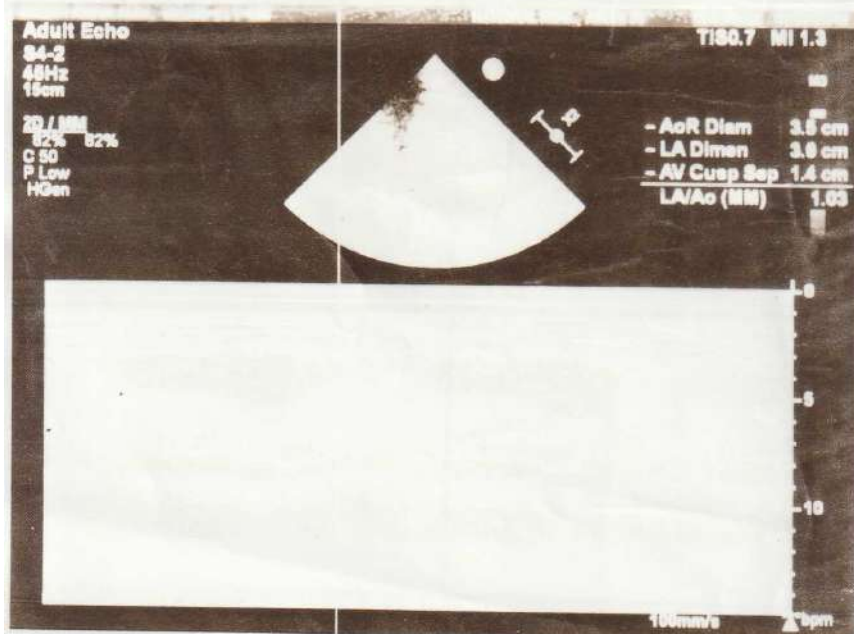
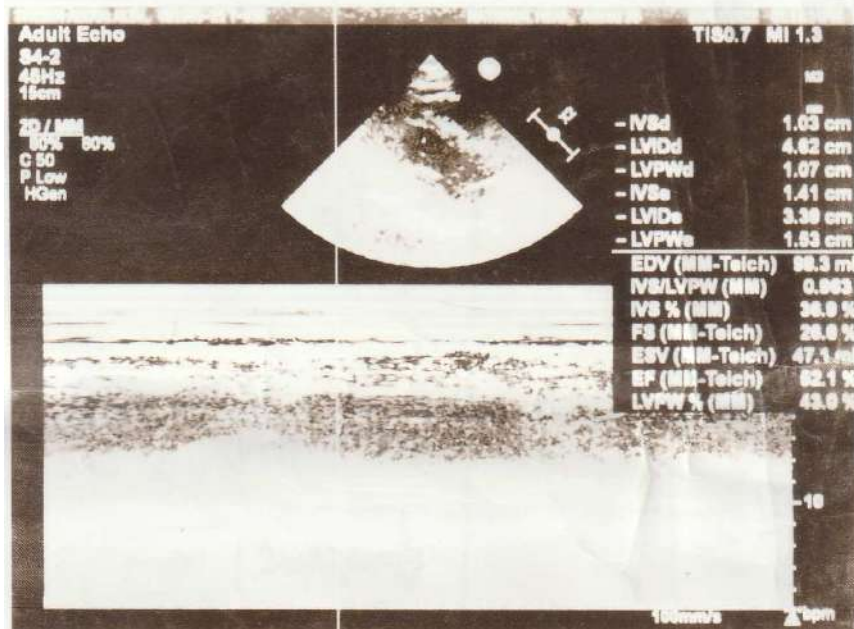
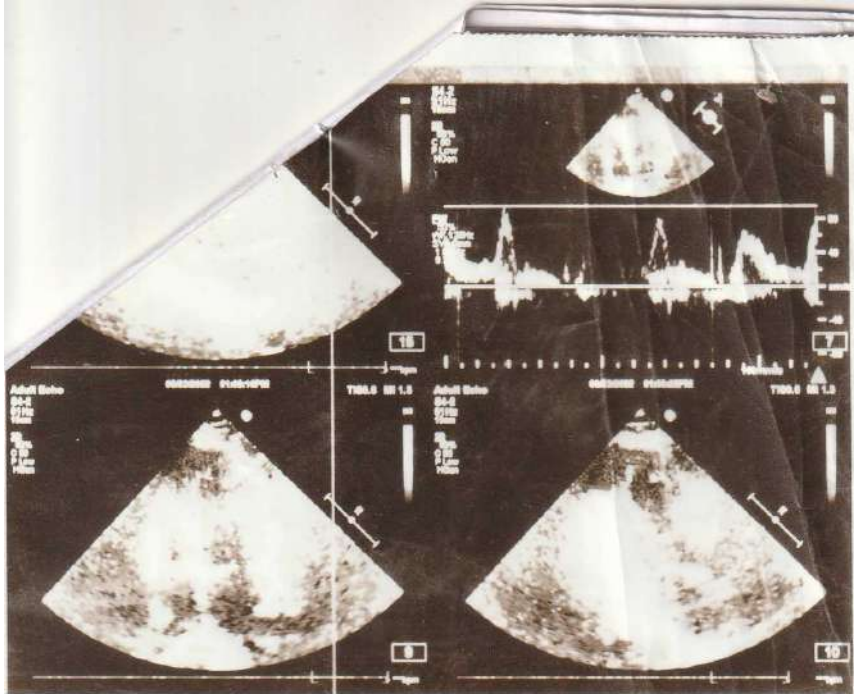
OLE:-
BP - 120/70 mmHg
Pulse - 72 b/min
Recent - S1, S2, S3
- Chest clear

Adv:-
Ech. v
Ech. - 2D

Adv:-
CAG+

Dr. Avimanyu Banik Rohan

6-Mar-22 10:06:55AM





ন্যাশনাল হার্ট ফাউন্ডেশন হাসপাতাল অ্যান্ড রিসার্চ ইনস্টিটিউট
NATIONAL HEART FOUNDATION HOSPITAL & RESEARCH INSTITUTE

ECHOCARDIOGRAPHY REPORT

Echo 2D and M-mode

Patient Id : 621366-21	Token : 335	Order No : 217864	Echo Date : 06/03/2022
Patient Name : Sheikh Abdul Alim		Requisition No : I-060322/1304889	
Age : 57y	Gender : Male	Ref. From : OPD	Printing Date & Time: 06/03/2022 2:06:45PM
Height : 0.00 cm	Weight: 0.00 Kg	BSA (m ²): 0.00	Ref. By : Dr. Wahid Sadique Anik

TEST	RESULT	UOM	TEST	RESULT	UOM
AOD	35	mm	Mitral EF Slope		cm/sec
LAD	36	mm	MV Annulus		mm
ACS		mm	TV Annulus		mm
IVST	10	mm	PV Annulus		cm ²
LVPWd	10	mm	MV Area		mm
LVIDd	46	mm	AV Area		-
LVIDs	33	mm	AV Ring		mm
LVEF	52	%	RVIDd		mm
FS	28	%	RVOT		mm
EPSS		mm			

Note: LVEF by Global Eye-ball estimation

Descriptions :	
ECHO Window	Good
Pericardium	Normal pericardium. No effusion seen
LV Wall Motion	Hypokinetic basal anteroseptum, basal mid IVS. LV systolic function is fair
RV Wall Motion	No RWMA seen. RV systolic function is good.
Valves	All valves are normal in morphology and motion.
Chambers	Normal
Wall Thickness	Normal
IAS	Intact
IVS	Intact
Intracardiac mass	No thrombus or vegetation seen.
Colour Doppler	Diastolic relaxation abnormality: A>E. AV gradient: 07/ 03mmHg.

Comments :

- Hypokinetic basal anteroseptum, basal mid IVS.
- Fair LV & good RV systolic function (LVEF: 52%).
- Normal chamber dimensions.

Dr. Md Nazrul Islam

Dr. Md Nazrul Islam
MBBS DTCD D-Card
Trained in Echocardiography
(Escort Heart Institute) New Delhi
Consultant Cardiologist

Prepared By: Ramicha

PLOT NO-7/2, SECTION-2, MIRPUR, DHAKA-1216, BANGLADESH.

Phone: 58054708-12, Fax: 48039237, Facebook: www.facebook.com/bangladesh.heartfoundation

www.nhf.org.bd E-mail : nhfadmin@agni.com, admin@nhf.org.bd