



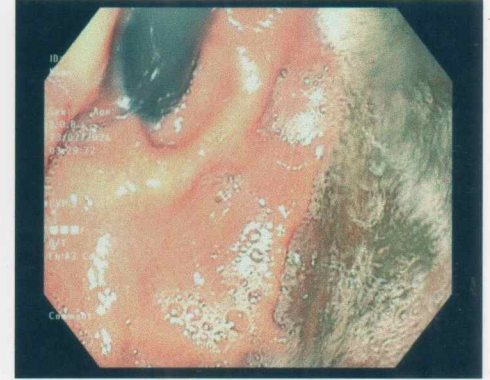
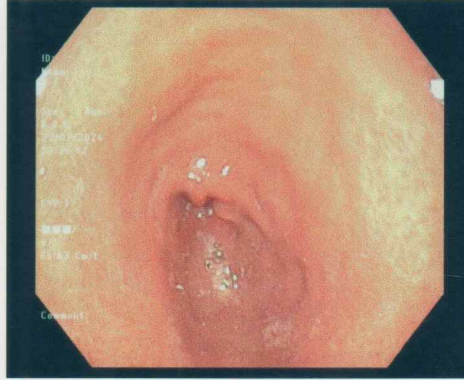
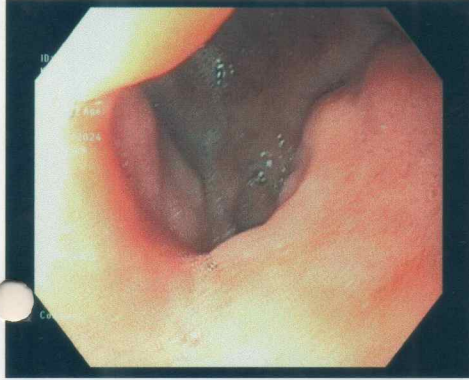
# POPULAR MEDICAL CENTRE LTD.

New Medical Road, Kazal Shah, Sylhet

Tel : 725227 Mobile: 01715-084078

Identity No.	18386	Visit Date	23 July, 2024
Patient Name	Mr Rinku Chakraborty	Age / Sex	48 / Male
History	N/A	Instrument	Olympus CV-170
Referrer	Prof Shishir Chakraborty FCPS(MEDICINE)	Bed	OPD

## ENSOPIC EXAMINATION REPORT



**Procedure :** Endoscopy of upper GIT

**Indication :** Dysphagia

**Medication :** Lidocaine Jelly 2%

Thanks for your kind referral.

### FINDINGS :

• **Oesophagus:-**

Lumen was compressed from outside up to 30 cm with tortuous vessels on surface. Rest of oesophagus was normal. G-E junction was at 40 cm from incisor teeth.

• **Stomach:-**

Diffuse erythema was seen at all areas. No varix was seen.

• **Duodenum:-**

Bulb was deformed and partially narrowed with diffuse erythema and scarring.

Post bulbar area up to second part appeared normal.

• **Biopsy:-** Not taken.

### COMMENTS :

- 1) External compression over upper oesophagus
- 2) Pangastritis
- 3) Chronic duodenal ulcer disease (duodenitis phase)

*Dr Madhusudan Saha*  
MBBS MD (Gastroenterology)

*23/7/2024*

