



USG 3D/4D REPORT



Pat ID : H12406466129	HN:	Counter 04
Pat No : E2406317497	Report No: 12406534901	Report Status: PREPARED
Pat Name : MRS. GULSHAN JAHAN	Invoice Date: 06/06/2024 11:28 AM	Delivery Date: 06/06/2024
Doctor : DR. SHAHANA YESMEN MBBS, BCS, MCPS, FCPS		Age/Gender: 55Y / F

name : USG-Breast Both

Right breast

- A hypoechoic mass is seen in LOQ at 9 o'clock position, measuring about (2.0 x 1.8 cm).
- A lymphnode is seen, measuring about (11.9 mm).

Left breast

- Left breast shows normal parenchymal echotexture.
- No mass or lesion is seen at present.
- A lymphnode is seen, measuring about (23.7 mm).

Comment:

- SOL in right breast.
- Bilateral axillary lymphadenopathy.

ADV- FNAC

With thanks for referral

6.6.24
Dr Nargis Sultana
MBBS Mphil
Diploma in medical ultrasound
Sonologist

Transcribed by: Efa

Transcribed by: All measurements including estimated fetal weight are subjected to statistical variation.
Please intimate us for typing mistake / misplacement of report if any & send the report for correction immediately.
Please bring all previous records including USG reports for reference.

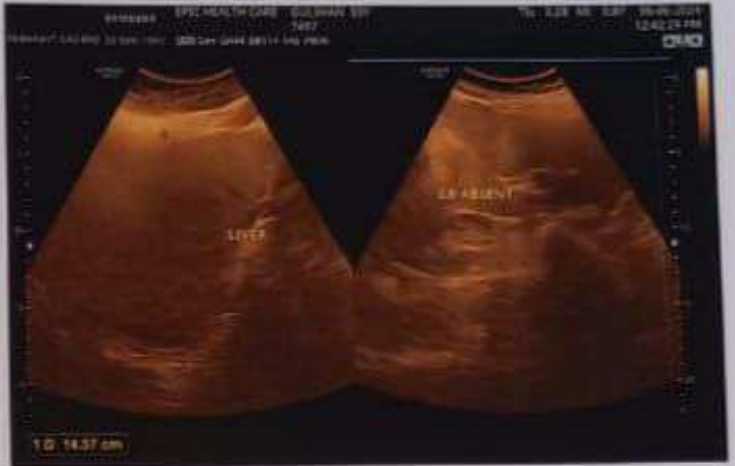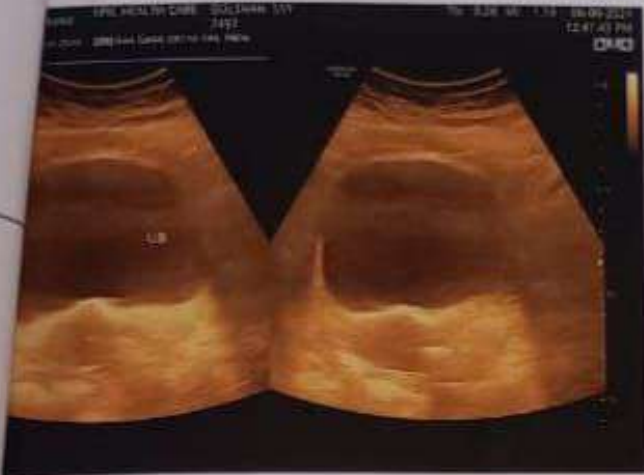Checked by:

7497
GULSHAN 55Y

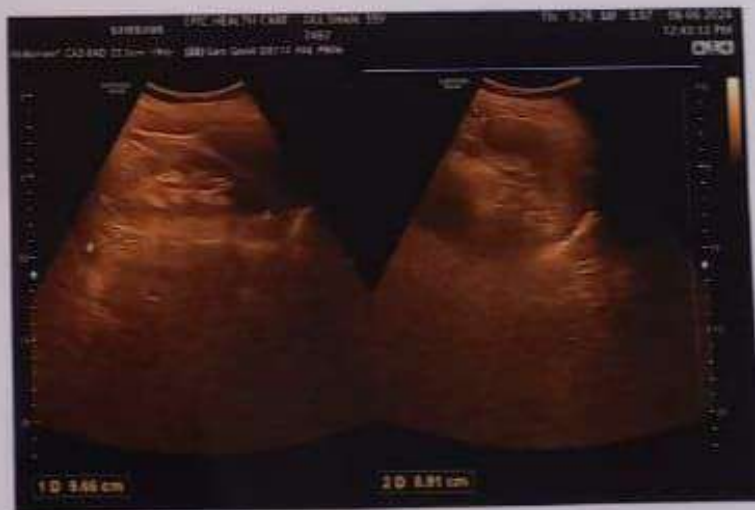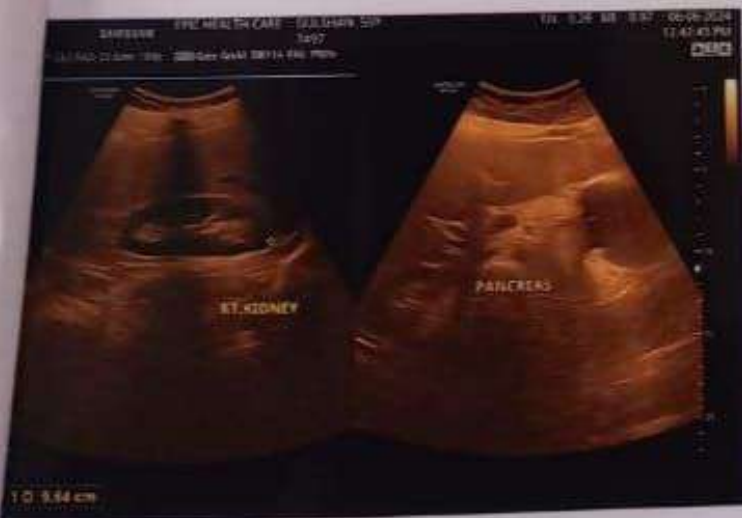Exam

Accession #
Exam Date
Description
Operator

06-06-2024



ng into

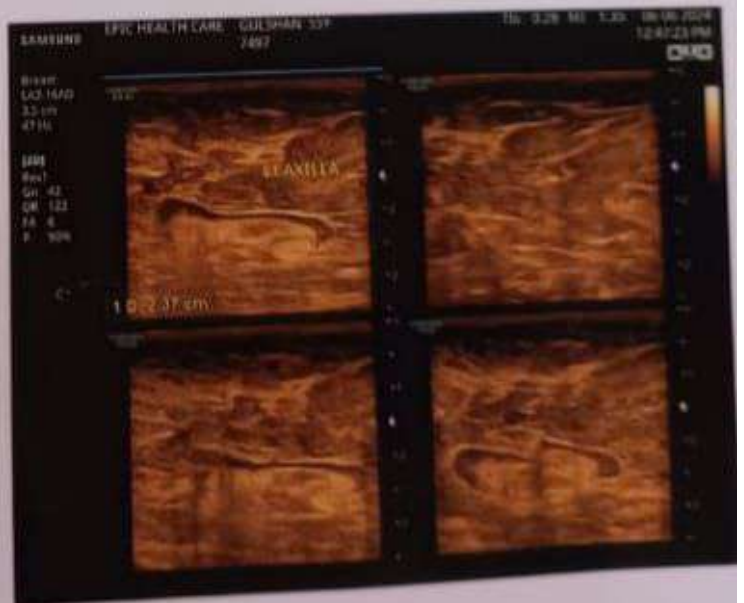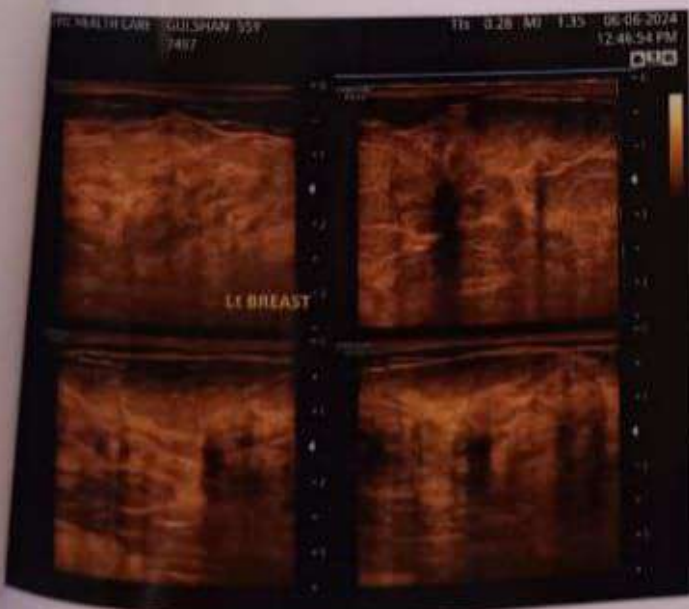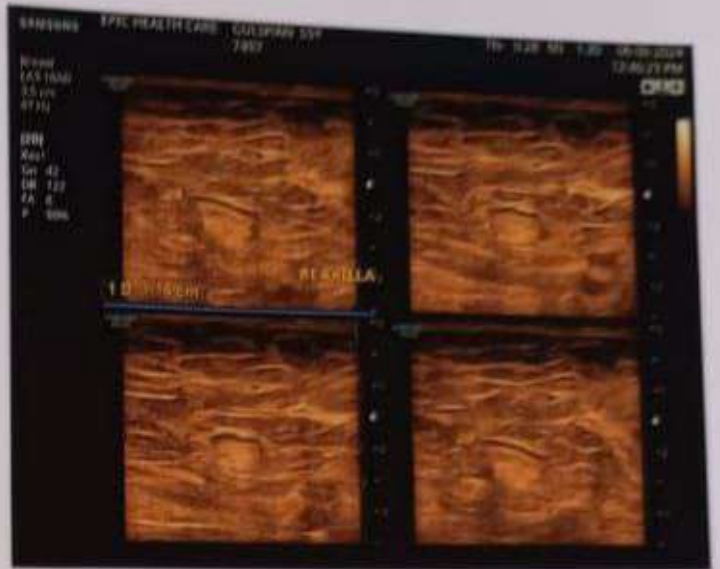
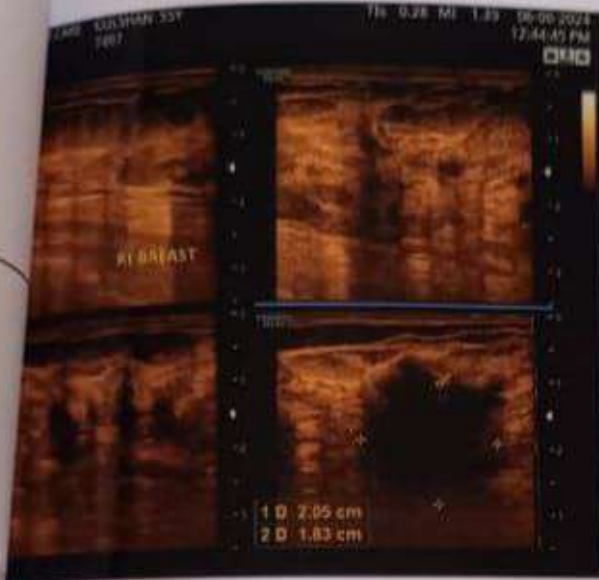


7497
GULSHAN 55Y

Exam

Accession #
Exam Date
Description
Operator

06-06-2024



**CT SCAN REPORT**

Patient ID : H12406477382
Invoice No : E2406326993
Patient Name : GULSHAN JAHAN
Ref. Doctor : DR. MINA AHMED BCS, FCPS Surgery

HN:
Report No: 12406542722
Invoice Date: 14/06/2024 10:44 AM

Counter 03
Report Status: PREPARED
Delivery Date: 14/06/2024
Age/Gender: 55Y / F

Test name : CT Scan-Whole Abdomen

CT SCAN OF WHOLE ABDOMEN**Protocol:**

Thank you for the reference.

A plain & post contrast spiral CT scan is performed using 5 mm slice collimation

Findings:

Liver is slightly enlarged in size with uniform enhancement. There is no focal lesion. Biliary trees are not dilated. Portal vein is normal.

Gall bladder is absent (Post surgical).

Pancreas is normal in size with no focal lesion. Vascular calcification is seen in the suprapancreatic region.

Spleen is normal in size with homogenous enhancement.

Abdominal aorta & IVC are normal.

Both adrenal glands are normal.

Both the kidneys are normal in size with excretion of good concentration of contrast. There is a minute radio-opaque calculus (2 mm) in upper polar calyx of the Lt. kidney.

Ureters & urinary bladder show no feature of note.

Prostate is normal in size with no focal lesion.

There is no obvious mass lesion in stomach, small gut & large gut.

Appendix is upper normal in caliber (8.7 mm) with thick enhancing wall. There is no periappendiceal soft tissue stranding.

No enlarged lymph nodes are noted in abdomen.

No collection of fluid is seen in peritoneal cavity.

Degenerative changes are seen in spine.

Interpretation: CT findings demonstrate:

- > Minute Lt. renal calculus (2 mm).
- > Mild hepatomegaly.

Reported by electronic signature

Prof. Dr. Didarul Alam

MBBS, MD (IPGMR)

Fellow MRI (Mumbai)

Advance Training in Oncology Imaging
& Cardiovascular CT (Singapore)

Ex. Head, Dept of Radiology & Imaging

USTC

ডাঃ মোঃ রাফিকুল হাসান
এমবিবিএস, এমডি (অন্যকোষাণু), ডিপিএস (স্বাস্থ্য)
ক্যান্সার বিশেষজ্ঞ (ট্রিনিডাদ অনকোলজি)
সহকারী অধ্যাপক, ক্যান্সার বিভাগ
চট্টগ্রাম মেডিকেল কলেজ হাসপাতাল
নিউমডিসি বেঙ্গি নং- এ ৪৭৭১০



Dr. Md. Rakibul Hasan
MBBS, MD (Oncology), BCS (Health)
Cancer Specialist (Clinical Oncology)
Assistant Professor, Department of Oncology
Chittagong Medical College Hospital
BMDC Reg. No. - A 47783

Name: Mrs. Gulshan Jahan

Age: 55

Sex:

Date: 15 JUN 2024

50 lbs

? Ca Lx Right Breast

FNM from right breast

lump → Ductal Carcinoma

i mucous coats

Adv:

① US guided
Core biopsy from right breast
lump

② US guided FNA from
both axillary node

US shows axillary
LAP in both
side

CA15-3, SAPF, Alkaline phospho

CAE P/A

Echocardiogram

পরামর্শ : দিন/সপ্তাহ/মাস পর দেখা করবেন। পরবর্তী সাক্ষাতের সময় ব্যবস্থাপত্র ও পরীক্ষার রিপোর্ট সাথে নিয়ে আসবেন।



ইবনে সিনা ডায়াগনোস্টিক এন্ড কনসালটেশন সেন্টার, চট্টগ্রাম। বাড়ী-১২/এ, রোড-০২, কাতালপল্ল, পাঁচলাইশ, চট্টগ্রাম।

সিরিয়ালের জন্য-হটলাইন : ০৯৬১ ০০০ ৯৬২২, অনলাইনে সিরিয়াল দিতে : Play store/Ibnasina Doctor Appointment

সময় : সন্ধ্যা ৭.০০টা থেকে রাত ৯.০০টা। (বৃহস্পতি ও শুক্রবার বন্ধ)। ফর্ম # ৬১৩

জরুরী প্রয়োজনে : ০১৭৭৭৯৯২২৬৬ এই WhatsApp নাম্বারে মেসেজ পাঠাবেন।

Facebook-এ ফলো করতে
Barcode স্কান করুন ▶



ডাঃ মিনা আহমেদ 0.47 = creatinine
 এমবিবিএস, বিসিএস (স্বাস্থ্য)
 এফসিপিএস (সার্জারী)
 সার্জারী বিশেষজ্ঞ
 সহকারী অধ্যাপক, সার্জারী বিভাগ

Brc. Asthma

Dr. Mina Ahmed

BCS (Health)
 FCPS (Surgery)

Surgery Specialist
 Asst. Professor, Surgery Department
 BMDC Reg. No. - A 36846

Name: Gulshan Jahan

Age: 55y Date: 18.06.24

wt = 52 kg

BP: 141 / 76 mm of Hg

C/E:

- Lumpiness on RT breast - 20 days
- occasional pain in lump

pl. do
 \bar{e}
 discont

Adv

- cBe
- eXR
- ECG
- Echocardiography
- FBS, 2HABF
- S. creatinine
- CT scan of whole abdomen

O/E:

Hot & diffuse lump on RT breast \bar{e}
 axillary lymphadenopathy

And

(Needs female oncologist)

A Ca Breast (RT)