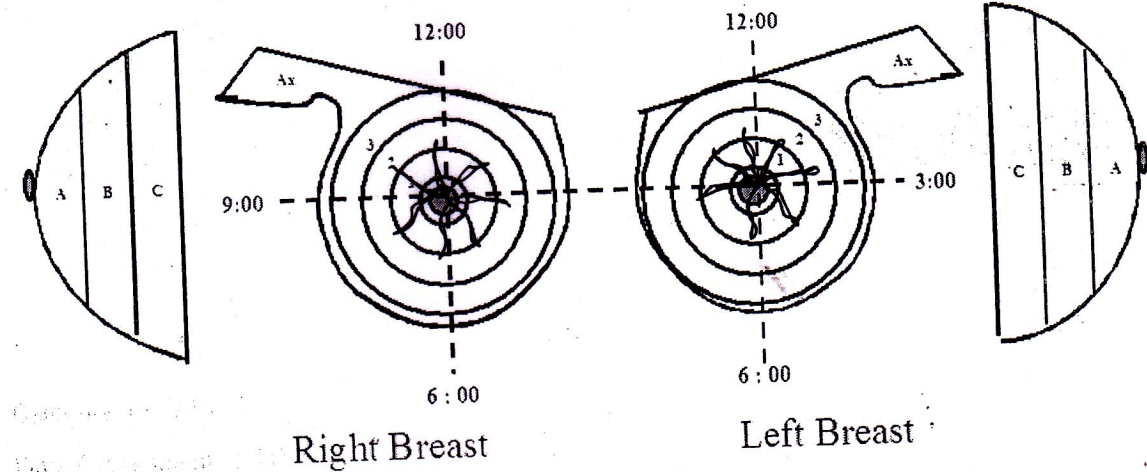


Category: BI-RADS-2

Final Assessment and Recommendation:

A benign finding

Routine screening recommended according to the age.



[SA = Subareolar area, 1 = Close to the nipple, 2 = Half way out of nipple,


3 = Lesion in the periphery, Ax = Axilla.

A = Very superficial, B = Midway down the breast, C = Deep near the chest wall]

RAD = Radial, AR = Anti radial

Rt : Periareolar : SA-1 A-B

Lt : Periareolar : SA-1 A-B


DR. SHARMIN AKHTAR RUPA
MBBS, M.Phil, FCPS
Professor
Department of Radiology & Imaging
Bangladesh Specialized Hospital Ltd.