

Date : 09-OCT-2023
Patient's Name : BELA RANI
ID : 23100597
Procedure : CAG
Admitted Under : Prof. Md. Rezaul Karim
Operator : Prof. Mashhud Zia Chowdhury

ইব্রাহিম কার্ডিয়াক
হসপিটাল এন্ড রিসার্চ ইনস্টিটিউট



IBRAHIM CARDIAC
HOSPITAL & RESEARCH INSTITUTE

(A Centre for Cardio Vascular, Neuroscience & Organ Transplant Units)

122, Kazi Nazrul Islam Avenue, Shahbag, Dhaka-1000

Tel: 88-02-41060451-58, Fax: 88-02-41060459

HOTLINE: 8801713 003004,10677

E-mail: info@ibrahimcardiac.org.bd, Web: www.ibrahimcardiac.org.bd

SAGAS-PRINTING-PRINT

28 11 2023



ইব্রাহিম কার্ডিয়াক

হসপিটাল এন্ড রিসার্চ ইনস্টিটিউট

122, Kazi Nazrul Islam Avenue
Shahbag, Dhaka-1000
Bangladesh



IBRAHIM CARDIAC

HOSPITAL & RESEARCH INSTITUTE

Tel : 9671141

Fax : 88-02-9635380

E-mail : info@ibrahimcardiac.org.bd

Date ০৯ -OCT-2023



ইব্রাহিম কার্ডিয়াক

হসপিটাল এন্ড রিসার্চ ইনস্টিটিউট

(A Centre for Cardio Vascular, Neuroscience & Organ Transplant Units)

122, Kazi Nazrul Islam Avenue, Shahbag, Dhaka-1000

Tel: 88-02-41060451-58, Fax: 88-02-41060459

HOTLINE: 8801713 003004, 10677

E-mail: info@ibrahimcardiac.org.bd, Web: www.ibrahimcardiac.org.bd



IBRAHIM CARDIAC

HOSPITAL & RESEARCH INSTITUTE

28 11 2023

স্বাগতম শ্রী: শাহজাহান
সিদ্দিকি, এমবিবিএস (এমবি)
ডিসি মাসুদুল হাসান
সিদ্দিকি হাসপাতাল

স্বাগতম শ্রী: শাহজাহান
সিদ্দিকি এমবিবিএস (এমবি)
ডিসি মাসুদুল হাসান
সিদ্দিকি হাসপাতাল
ISO 9001:2008 QMS Certified Hospital

Prof. Dr. Masoom Siraj
MBBS, FRCGS
Senior Consultant & Head
Cardiac S

Name: Bela Ravi (N.t parent)

Age: 55 yrs

Edn: ICHAI EFF657

CR: JCHART LAD DM2 RCR

Adn: Early CRAS Masoom Siraj
10/11/23

28 11 2023



122, Kazi Nazrul Islam Avenue, Shatabdi, Dhaka-1000, Bangladesh
Tel: 88-02-4196045-56, Fax: 88-02-4196045/9, Personal: 01711-594096, E-mail: masoomsiraj@masoomsiraj.com



EXCELLENCE IN HEALTH CARE



28 11 2023

Invoice No : 0653301023 Invoice Date : 09/10/23 Delivery Date : 09/10/23 Report No : 12310018788
 Patient Name : BELLA RANI Age : 55Y 1D Gender : Female
 Referred By : Prof. Md. Rezauul Karim Patient ID : 231005587
 Sample : NASAL SWAB LAB No : 12310021598
 Tests : COVID-19 Antigen Rapid Test
 Col. Temp. : 36.5°C 34 min Receive Time : 09/10/23 09:27 am

| Test | Result |
|-----------------------------|----------|
| COVID-19 Rapid Antigen Test | Negative |

Note:
 Kit used: Panbio, Abbott, USA. Sensitivity 94.1%, correlated with RT-PCR = 33 cycle, Specificity 99.9%
 Specimen: Nasal Swab/np Swab. Method: Lateral Flow Immunochromatography

Comment:
 • A negative result means that the person is unlikely to have Covid-19 infection provided the patient does not present any Covid-19 related symptoms or any history of contact during the last 10 days.
 • A positive rapid antigen result means that the person may be infected with COVID-19. However, antigen tests may occasionally produce false positive results, and it needs a SARS-CoV2-PCR test to be done in order to confirm the result.

Caution:
 • Antigen RPOCT is used for screening purposes only and NOT for diagnostic purposes.
 • Antigen RPOCT should NOT be used to test for COVID-19 infection in symptomatic individuals or individuals with known close contact with a positive COVID-19 case.
 • Antigen RPOCT does not replace public health measures such as vaccination, symptom screening, physical distancing, masking and hand hygiene.
 • Antigen RPOCT is appropriate for use in asymptomatic individuals only.
 • Antigen RPOCT screening testing is, generally, not recommended for individuals who are fully vaccinated (i.e. ≥14 days after receiving their second dose of a two-dose COVID-19 vaccine).
 Not
 • WHO REFERENCE NUMBER: WHO/2019-nCoV/antigen_Detectors/2021.1
 • Version Guidance for Antigen Testing for SARS-CoV-2: Centers for Disease Control and Prevention. Updated Sept 9, 2021.

PHONAB GHOSH
 Medical Technologist
 Diagnostic Laboratory Services

MD. MURAD HOSSAIN
 B.Sc (Pharm), MS
 (Biochemistry and Molecular Biology)
 Senior Scientific Officer
 Diagnostic Laboratory Services

Report Status : Finalized

Powered by: MICRO TISS



(A Centre for Cardio Vascular, Neurosciences & Organ Transplant Units)

An Enterprise of the Diabetic Association of Bangladesh
ISO 9001 - 2008 QMS Certified Hospital

Discharge Treatment
(for Pharmacy Use)

Patient ID : 23100997 Patient Name : BELA RANI Admission Date : 09-10-2023
Gender : Female Age : 55 Y Discharge Date : 10-10-2023
Weight (kg) : 47 BMI : 21kg/m² Code No : 23100997

28 11 2023

| Medicine Name | Dosage | Timing | Duration |
|-------------------------|-------------|-------------|---------------|
| 1 Tab. Escaprin 75mg | 0+1+0 | after meal | Continue |
| 2 Tab. Pantocix 20mg | 1+0+1 | before meal | Continue |
| 3 Tab. Lipicon 20mg | 0+0+1 | before meal | Continue |
| 4 Tab. Nitrocorin 6.4mg | 1+1+0 | | Continue |
| 5 Tab. Duracec 25mg | 1+0+1 | | Continue |
| 6 Tab. Ramipril 500 mg | 1+0+1 | | Continue |
| 7 Tab. Thyrox 25 mcg | 1+0+0 | before meal | Continue |
| 8 Spray Nasa | 1+2oufts SL | | if chest pain |

Advice : * Low in animal fat
Diet : * CABG
Advised for : * CABG

Please confirm the appointment
on following phone numbers :
01714-006706 or Hotline : 10677

Prof. Md. Razzak Karim
MBBS (D.U.), D-Card (London)
WHO-Fellow in Cardiology, India
Professor & Sr. Consultant

Developed & Maintained by: www.junehoa.info
Drug Database by: Incepta Pharmaceuticals Ltd

Discharge Summary

180 West 20th Street, Cambridge, MA 02142

Patient ID: 23100007 Name: **HELIA HANI** Age: 50 Y
 Gender: Female Contact No: 0117383838 Bed No: A-0201
 Room No: 110 Address: BAHADURA, 270th, SUITE, 200 Adm No: QANON 02
 Weight (kg): 47 Height (cm): 158 DOA: 08-10-2023
 Adm (Report): 21 DOB: 19-10-2023

Present Diagnosis: **Coronary Artery Disease** Date: 08/10/2023
 Hypertension (I10) Type: severe disease Date: 08/10/2023
 Type: severe disease
 Risk Factors:

Case Summary:
 This 50-year-old hypertensive, non-diabetic, dyslipidemic lady known case of Hypertension got admitted for elective CABG with the complaints of exertional pallidness & SOB for last 3 years. She underwent ETT on 27/02/2023 which was positive for moderate myocardial ischemia & achieved 7.20 METs. On admission her Pulse - 66 bpm, BP - 100/70 mmHg, Heart - S1+S2+S3, Lung - VDD, ECG showed Q in III, aVF. Echo revealed no regional or global wall motion abnormality, good LV systolic function (EF=65%), diastolic dysfunction (Gr. II), mitral stenosis.

Rapid Angiogram test for COVID-19 was done on 08/10/2023 which was Negative.
 CABG was done on 08/10/2023 which revealed Triple vessel disease and was recommended for CABG.
 Double coronary circulation was done and advised for Early CABG.
 She is being discharged with the following medications & advice.

Treatment:

| Brand Name | Generic Name | Dosage | Timing | Duration |
|---------------------------|------------------------------|-------------|-------------|--------------|
| 1. Tab. Escoron 75mg | Aspirin | 75+150 | after meal | Continue |
| 2. Tab. Perindopril 20mg | Perindopril | 1+2+1 | before meal | Continue |
| 3. Tab. Lipitor 20mg | Atorvastatin | 20+1 | before meal | Continue |
| 4. Tab. Metformin 640mg | Metformin (extended release) | 1+1+1 | | Continue |
| 5. Tab. Isosorbide 20mg | Isosorbide | 1+0+1 | | Continue |
| 6. Tab. Isosorbide 500 mg | Isosorbide | 1+0+1 | | Continue |
| 7. Tab. Thyrox 25 mg | Letrothyron Sodium | 1+0+1 | before meal | Continue |
| 8. Spray Mucin | Acetylcysteine (inhalation) | 2Sprays, 3X | | 8 (over 8pm) |

Diet: * Low in sodium diet.
 * CABG

Lab Result:

| Test Name | Result | Reference Value |
|--------------------------------------|----------|-----------------|
| Fast Fasting HbA1c (%) | Negative | |
| ASAT Blood Group | Negative | |
| Prothrombin Time (PT) (s) | 13.7 | 9.0 - 13.0 |
| International Normalized Ratio (INR) | 1.1 | 0.8 - 1.1 |
| Total Cholesterol | 164 | 0 - 200 |
| HDL Cholesterol | 33 | 30 - 35 |

28 11 2023

Discharge Summary

ISS: 9991-2008 Cardiac Center

Patient ID : 23100937 Name : BELA RANI
 Gender : Female Contact No : 0173666399
 Blood Group : O+ Address : BARKHARDA, KULNA, KUSTHIA, BD
 Height (cm) : 149 Weight (kg) : 42 Age : 55 y
 BMI (kg/m²) : 21 Code No : CHOW WIP-02
 Adm No : 1 Code No : 23100937
 DOA : 08-10-2023
 DOD : 10-10-2023

Previous Diagnosis : Current Diagnosis : Coronary Findings :
 Hypertension (HTN) Type vessel disease 09/10/2023
 Hypertension (HTN) Dyslipidemia Type vessel disease Type vessel disease

Case Summary
 Bela Rani, 55 yrs old, hypertensive, non diabetic, dyslipidemic lady known case of Hypothyroidism got admitted for elective CABG with the completion of preoperative evaluation & SCB for last 3 years. She underwent ETT on 21/10/2023 which was positive for preoperative myocardial ischemia & achieved 7/30 METs. On admission her Pulse-66 bpm, BP-100/70 mmHg, Heart-RS1-52+0, SaO₂-98%, VBS-ECG showed Q in III, IV, ECG revealed no regional or global wall motion abnormality, good LV systolic function (EF=65%), diastolic dysfunction (Gr-II), acute echocardiogram.

Rapid Antigen test for COVID-19 was done on 09/10/2023 which was Negative
 CABG was done on 09/10/2023 which revealed Triple vessel disease and was recommended for CABG.
 Cardiac Surgery consultation was done and advised for Early CABG.

Note: she is being discharged with the following medications & advice.

Treatment

| Brand Name | Generic Name | Dosage | Timing | Duration |
|--------------------------|-------------------------------|------------|-------------|---------------|
| 1. Tab. Ecosopent 75mg | Aspirin | 6+1+0 | after meal | Continue |
| 2. Tab. Plavixon 200mg | Prasugrel (Sulfinpyrazone) | 1+0+1 | before meal | Continue |
| 3. Tab. Lipson 200mg | Atorvastatin | 0+0+1 | before meal | Continue |
| 4. Tab. Nitrocoron 6.4mg | Oxymetazoline (oxymetazoline) | 1+1+0 | | Continue |
| 5. Tab. Atenolol 25mg | Atenolol | 1+0+1 | | Continue |
| 6. Tab. Harnuz 500 mg | Venipipride Salts | 1+0+0 | before meal | Continue |
| 7. Tab. Thyron 25 mcg | Oxymetazoline (oxymetazoline) | 1-2pds BID | | if chest pain |
| 8. Spray Nabilin | | | | |

Advice
 * Live in animal fat.
 * CABG

Test Result

| Date & Time | Test Name | Result | Reference Value |
|----------------------|--------------------------------------|--------------------------|-----------------|
| 09-10-23 12:00:00 AM | Audit/ICV | Negative | |
| | Audit/IV | Negative | |
| | Audit Blood Group | O+ | |
| | Diastolic Typing (Tb-D) | Positive (Type) | 66-70 |
| | Prothrombin | 47% | |
| | Prothrombin Time (PT) | 5.94 x 10 ³ s | 4-11 |
| | Partial Thromboplastin Time (PTT) | 0.9% | 2-8 |
| | International Normalized Ratio (INR) | 33 g/dl | 10-35 |
| | MC-HC | | |

28 11 2023



Discharge Summary

500 9691 - 2008 (Date: 28/11/2023)

28 11 2023

Patient ID : 23100597 Name : BELA RAMI

Age : 50 Y

Date & Time : 28-11-2023 12:00:00 AM

| Test Name | Result | Reference Value |
|------------------|----------------------------|-------------------|
| Heart Size Count | 4.23 x 10 ¹⁰ /L | 3.5 - 6 |
| Leucocytes | 17.2 g/dl | Male: 13.2 - 10.8 |
| Hemoglobin | 05 % | 0 - 1 |
| HCT | 28.7 % | 27 - 32 |
| Hematocrit | 04 % | 02 - 08 |
| Platelets | 283 x 10 ⁹ /L | 150 - 450 |
| HCTV | 87.1 % | 77.98 |
| Leucocytes | 3.7 % | 37 - 52 |
| lymphocyte | 45 % | 20 - 40 |
| CD4/10-19 Ratio | Negative | |
| HIV Ab | Negative | |
| Control | NA | |
| RAI | 1.0 | |
| Parameter | 14.1 Spc | 12 - 10 |
| Hemoglobin | 7.3 mmol/L | < 7.8 |
| S. Cholesterol | 0.68 mg/dl | Adult 0.8 - 1.8 |
| S. Proteasium | 3.8 mmol/L | 3.0 - 8.1 |
| B. Sodium | 140 mmol/L | 136 - 145 |
| UREA / AL T | 22 U/L | 3 - 20 |
| TP/TA | Negative | |

ECG

28-11-2023 Qr II, III, aVF

ECG

28-11-2023 No regional or global wall motion abnormality, good LV systolic function (EF=45%), dilated right ventricle (D=11), acute ischemia

XRAY

28-11-2023 Bilateral cardiomegaly

Muhammad Mustafa
Dr. Mubashir Mustafa
Senior Consultant

Muhammad Mustafa
Prof. Mubashir Mustafa
MBBS (Dipl. Cardiol),
MCh (Fellow in Cardiology),
Fellowship in Interventional
Cardiology

For more information or appointment for Laboratory Information System (www.zymolab.com)



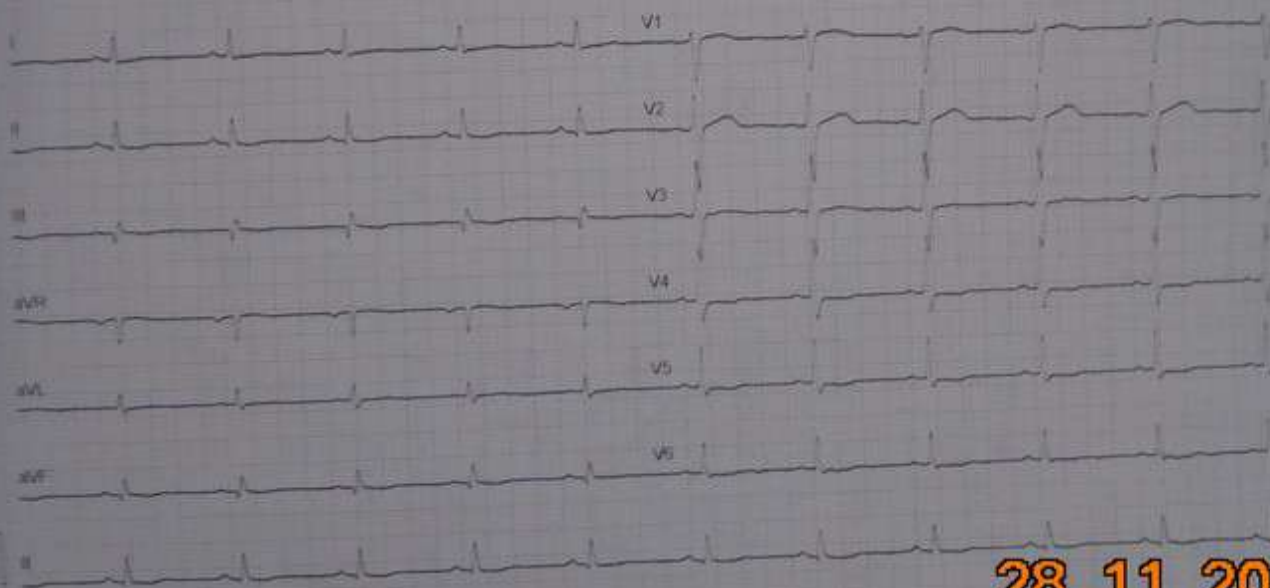
122 Kazi Nazrul Islam Avenue, Shahbagh, Dhaka-1000, Bangladesh.
Phone: +8802461-84, 84, 204, 207, 0175400001, Fax: 88024100004, Email: info@ibrahimcardiac.com, www.ibrahimcardiac.com

Scanflow or Scanflow Plus

QRS 84 ms
QT / QTc Baz 409 / 427 ms
PR 122 ms
P 54 ms
RR / SP 912 / 909 ms
P / QRS / T 91 / 26 / -58 degrees

Normal sinus rhythm
Possible inferior infarct, age undetermined.
ST & T wave abnormality: consider lateral ischemia
Abnormal ECG

Bella Ford
AFLW-02
df - 20.80A, M
0.01 - 10.10.23.



28 11 2023

Unconfirmed

Hrs. 3.45 km - 5.15 -

07 OCT 2023

H 7th . Hypertension

CC - DMHHTK

- Exertional EMS

- Tab. Euvigam - 35

- 744 100 - 25

140 x 0 -

- N. NIKO control - 6.4

140 x 1

- N. Nemo 300 - 500

120 x 1

- 2 - Lignosin - 30

02 0 x 1 -

- 4 - Progynt - 30

0 x 0 x 1 -

- N. Butolac - 25

140 x 1 -

Ar - ECR (M)

X Echo (N)

- CFR-1A - (M)

- E77 (+V)

- 7.1H - (M)

Ar
 → CAD

28 11 2023



Ibrahim Cardiac Hospital and Research Institute
CORONARY ANGIOGRAM / PCI REPORT



Ref No: 00924 Hospital Reg No: 21122201
Name: BELA NUR
Address: 141 Buranda Zula, Kuala 80

Case No: 504 Date: 09-Oct-23
Age: 55 y Weight: 160 cm Wt: 47 kg

Referring Physician: Prof Dr. Masbudi Za Chomahury

Diagnosis: Angina (I - II), HTN

Allergy: Not known

Risk Factors: • Hypertension
Vital: normal level

EKG: No ST-TU, VET - 67%
ETT:
ECHO:

Coronary Angiogram Report

Assisted by: Dr. Mo Ahmad Han

Performed by: Prof. Dr. Masbudi Za Chomahury

Indication: Right Radial Approach, (R) sheath
Vascular Access: Arterial - 370
Drugs used: 5 Ft, TIO
Catheter Used: Procedure was uneventful
Procedures related
Comments:

LMB: LAD has no significant disease.
LAD: Mid LAD has 90% stenosis.

LCA: Non dominant, LCA is occluded from mid part with retrograde flow from collateral & contrast medium.
MCA: Dominant, RICA is occluded from proximal part with TIMD 0-1 flow with retrograde flow through collateral.

LV Grady: Mild trace
Comment: Right vessel disease

Recommendation: CABG

28 11 2023

MR
Prof. Dr. Masbudi Za Chomahury
Head of Cardiology & Professor

ইব্রাহিম কার্ডিয়াক
হসপিটাল এন্ড রিসার্চ ইনস্টিটিউট
(A Centre for Cardio Vascular, Neuroscience & Organ Transplant Units)



IBRAHIM CARDIAC
HOSPITAL & RESEARCH INSTITUTE

ISO 9001:2008 QMS Certified Hospital

DIAGNOSTIC LABORATORY SERVICES

COAGULATION TEST REPORT

AN :



Sample No : 0454241023
Patient Name : BELLA RANI
Requested by : PSM-08

Invoice Date : 09/10/23
Delivery Date : 09/10/23
Age : 55Y 10

Report No : 12210019028
Gender : Female
Patient ID : 23100597

LAB No : 12310001792

Sample : 8L000
Tests : PT (Prothrombin Time)
Cat. Code: 201022310 44 pm

Receive Time : 09:42:00 pm

| Test | Result | Units | Reference Range |
|------|--------|-------|-----------------|
|------|--------|-------|-----------------|

PT (PROTHROMBIN TIME)

Control
Patient
UIB

| | | | |
|------|--|-----|---------|
| 14 | | | |
| 14.1 | | Sec | 12 - 15 |
| 1.0 | | | |

HN :

Report Status : Finalized

MOSHAMMAD IRRIS ALI SHEIKH

Lab in Charge
Medical Technologist
Department : Chemistry Services

DR. KHALEDA AKTER
Senior Laboratory
Department : Chemistry Services

Approved by:

Approved & Issued : 09/10/2023 09:41:54 PM

28 11 2023

ইব্রাহিম কার্ডিয়াক
হসপিটাল এন্ড রিসার্চ ইনস্টিটিউট
(A Centre for Cardio Vascular, Neuroscience & Organ Transplant Units)



IBRAHIM CARDIAC
HOSPITAL & RESEARCH INSTITUTE

ISO 9001:2008 QMS Certified Hospital

DIAGNOSTIC LABORATORY SERVICES

HAEMATOTOLOGY REPORT

Report No: 12310019025
Gender: Female
Patient ID: 23100597

Age: 55Y 1D

Delivery Date: 09/10/23

Invoice Date: 09/10/23

LAB No: 12310021790

Sample: R0000
Tests: CBC
Date Time: 09/10/23 11:44 pm

Reactive Time: 09:02:02.24 pm

| Test | Result | Units | Reference Range |
|------|--------|-------|-----------------|
|------|--------|-------|-----------------|

RED CELLS
Hemoglobin

| | | |
|------|------|------------------------------------------|
| 12.2 | g/dl | Male: 13.2 - 16.0 Female: 11.6 - 15.0 |
|------|------|------------------------------------------|

RBC Count

| | | |
|------|---------------------------|---------|
| 4.25 | $\times 10^9/\mu\text{L}$ | 3.5 - 6 |
|------|---------------------------|---------|

Hematocrit

| | | |
|----|---|---------|
| 37 | % | 37 - 52 |
|----|---|---------|

MCV

| | | |
|------|----|---------|
| 87.1 | fL | 77 - 99 |
|------|----|---------|

MCH

| | | |
|------|----|---------|
| 28.7 | pg | 27 - 32 |
|------|----|---------|

MCHC

| | | |
|----|------|---------|
| 33 | g/dL | 30 - 36 |
|----|------|---------|

WHITE BLOOD CELLS
Total Count

| | | |
|------|---------------------------|--------|
| 5.94 | $\times 10^9/\mu\text{L}$ | 4 - 11 |
|------|---------------------------|--------|

Differential Count

Neutrophil

| | | |
|----|---|---------|
| 47 | % | 50 - 70 |
|----|---|---------|

Lymphocyte

| | | |
|----|---|---------|
| 45 | % | 20 - 40 |
|----|---|---------|

Monocyte

| | | |
|----|---|-------|
| 04 | % | 2 - 8 |
|----|---|-------|

Eosinophil

| | | |
|----|---|---------|
| 04 | % | 02 - 06 |
|----|---|---------|

Basophil

| | | |
|----|---|-------|
| 00 | % | 0 - 1 |
|----|---|-------|

Platelets


| | | |
|-----|---------------------------|-----------|
| 263 | $\times 10^9/\mu\text{L}$ | 150 - 450 |
|-----|---------------------------|-----------|

Report Status: Finalized

HN:

MOHAMMAD IDRIS ALI SHEIKH
Senior Consultant
Medical Microbiology
Diagnostic Laboratory Services

Dr. KHALEDA AKTER
MBBS (Medicine)
Specialist (Laboratory)
Diagnostic Laboratory Services



Phone & Fax: 99004180-990022 98473810

122, Road Nazim Islam Avenue, Station, Dhaka-1000. Tel: 99004180-990022, Fax: 278 (1x24), 277 (24x7), 284 (24x7) (Toll Free)
Call: 9917440070 (Emergency), 01711090706, Fax: 99004180, Emergency/Admission Number: 01773400004, E-mail: info@ibrahimcardiac.org

MAXIMUM HEALTH CARE

28 11 2023



(A Centre for Cardio Vascular, Neuroscience & Organ Transplant Units)

An Enterprise of the Diabetic Association of Bangladesh

ISO 9001 - 2008 QMS Certified Hospital

X-RAY REPORT

| | | | |
|----------------|------------------|------|-------------|
| Patient ID | : 23100597 | Date | : 9.10.2023 |
| Patient's Name | : Bela Rani | Age | : 55 Yrs |
| X-Ray of | : Chest P/A View | | |

28 11 2023

CHEST X-RAY P/A VIEW

Findings:

- Lung Field : No definite infiltrative lesion, collapse or consolidation is seen in either side of visible lung fields.
- Heart : **Borderline enlarged in transverse diameter.**
- Diaphragm : Domes of the diaphragm are normal in position, contour and definition Both the CP angles are clear.
- Bony thorax : Visible bones appear unremarkable.
- Impression : **Borderline cardiomegaly.**
Please correlate clinically.

Dr. Jesmin Ara Farven
MBBS, MD (CU)
Assistant Prof & Assoc Consultant
Radiology & Imaging
ICMR



ইব্রাহিম কার্ডিয়াক
হসপিটাল এন্ড রিসার্চ ইনস্টিটিউট
(A Centre for Cardio Vascular, Neuroscience & Organ Transplant Units)



IBRAHIM CARDIAC
HOSPITAL & RESEARCH INSTITUTE

ISO 9001:2008 QMS Certified Hospital
DIAGNOSTIC LABORATORY SERVICES

BLOOD BANK REPORT

Invoice No : 0854241023 Invoice Date : 09/10/23 Delivery Date : 09/10/23 Report No : 1231001823
Patient Name : BELLA RANI Gender : Female
Referred by : PSW-06 Age : 55Y 1D Patient ID : 23100597

Sample : BLOOD LAB No : 12310021723
Tests : Blood For Grouping and Typing Receive Time : 09/10/23 07:17 pm
Call Time: 09/10/23 01:44 pm

| Test | Result |
|-----------------------|----------------|
| ABO Blood Group | "O" |
| Rhesus Typing (Rh. D) | Positive (+ve) |

HN : 

Report Status : Finalized

Powered by: MYSOFT Ltd

OR
MOHD. MIZANUR RAHMAN
Medical Technologist
Diagnostic Laboratory Services
Ibrahim Cardiac Hospital & Research Institute

OR
Rechecked By
Medical Technologist (Blood Bank)
Diagnostic Laboratory Services

Doleda
DR. KHALEDA AKTER
MBBS, MD(Biochemistry)
Specialist (Laboratory)
Diagnostic Laboratory Services

Computer Generated Report

28 11 2023