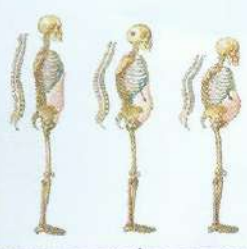


Form the Desk of  
**Prof. Dr. Anwarul Islam Choudhury**

MBBS, MS (Ortho), FICS (USA)  
**Consultant Ortho & Trauma Surgeon**  
 Ex-Chairman, Department of Orthopaedics  
 BSM Medical University, Dhaka  
 BMDC Reg. No: 5089



Ht. 5'6" Wt. 753-682  
**Chamber :**  
 Choudhury Ortho-Trauma Center  
 Dhaka Road, Gazipur Chowrasta, Gazipur.  
**Time 09 AM To 12 PM Daily (Except Friday)**  
 E-mail: prof.aichoudhury@gmail.com

Name: Mr. Gopal ch Sahas Age: 55y Date: 26.10.23

HO  
370  
 Pain in lvs  
 + hip + ankle  
 Difficult to walk  
 over weight (75 → 682)

Rx

Advice  
 ① Reduce body weight  
 ② Green Vegetables  
 ③ Daily walk x 90m  
 ④ RSE of Rt lvs  
 Mu = Walking in mud

R/E  
Rt is Day

Rx  
 ① 120 Naproxen 8250 (40)  
 ② Cap. Maxipro 1-x-1 (29)  
 ③ Rt Galcin 1-x-1

26/10/23

④ 20 Tenidyl (31)  
 x-x-1





# রেডিয়াম ডায়াগনস্টিক সেন্টার RADIUM DIAGNOSTIC CENTRE

Unit-2 : H-98, Swad Bhaban, Central Jame Masjid Road, Joydebpur, Gazipur.  
Hot Line : 09612668866, Mobile : 01713452238, 01708527419, 01886452240

Invoice No : **23085580**

Patient's Name : Mr.Gopal Chandra Saha

Specimen : BLOOD

Investigation : CBC,ESR

Ref. By : Prof. Dr. Anwarul Islam Chowdury MBBS MS (Ortho) FICS (USA)

Inv Date: 28-10-2023 Delivery Date : 28/10/2023

Age : 55 yrs Gender : Male

Coll Time: 28/10/2023 12:31:58 PM Name: Azahar

Phone :



## Haematological Report



Reports generated by Auto Haematology Analyzer **SYSMEX -XS-800i** and checked manually

Test Name	Result	Unit	Reference Range
Haemoglobin(Hb%)	<b>13.1</b>	g/dL	M:13-18, F: 11.5-16.5, Ch:10 - 13
ESR (Westergren Method)	<b>05</b>	mm/h	M: 0 -10, F: 0 - 20 mm in 1st hr
<b>Total Count</b>			
White Blood Cell	<b>9,150</b>	/cumm	4,000 - 11,000 /cumm
Red Blood Cell	<b>4.44</b>	million/cumm	M: 4.5-6.5, F: 3.8-5.8 ,Ch: 4.7-5.7
Platelet Count	<b>2,28,000</b>	/cumm	1,50,000 - 4,00,000 /cumm
Cir.Eosinophils Count	<b>180</b>	/cumm	50 - 400 /cumm
<b>Differential Count</b>			
Neutrophils	<b>73</b>	%	Child ( 25 - 66 % ), Adult ( 40 - 70 % )
Lymphocytes	<b>21</b>	%	Child ( 40 - 60 % ), Adult ( 20 - 45 % )
Monocytes	<b>04</b>	%	Child ( 02 - 07 % ), Adult ( 02 - 10 % )
Eosinophils	<b>02</b>	%	Child ( 00 - 03 % ), Adult ( 01 - 05 % )
<b>Others</b>			
Haematocrit(HCT)	<b>37.0</b>	%	M: 40 - 54, F: 37 - 47 %
MCV	<b>83.3</b>	fL	79.00 - 97.00 fL
MCH	<b>29.5</b>	pg	27.00 - 34.00 pg
MCHC	<b>35.4</b>	g/dL	31.00 - 39.00 g/dL
RDW-CV	<b>12.8</b>	%	12.8 ± 1.2 %
MPV	<b>12.5</b>	fL	9 - 13 fL
P-LCR	<b>44.6</b>	%	13 - 43 %
PCT	<b>0.28</b>	%	<= 0.9%

**Md. Mofazzol Hossain**  
D.M.T (Lab. medicine) Dhaka  
Medical Technologist (Lab)  
Radium Diagnostic Center, Gazipur

**Md. Ali Tareq**  
D.M.T (Lab. medicine) Dhaka  
Medical Technologist (Lab)  
Radium Diagnostic Center, Gazipur

**DR. MD. MIJANUR RAHMAN**  
MBBS, DCP(BSMMU)  
Consultant Clinical Pathologist  
Uttara Adhunik Medical Collage Hospital

Printed By: Kanai





# রেডিয়াম ডায়াগনস্টিক সেন্টার RADIUM DIAGNOSTIC CENTRE

Unit-2 : H-98, Swad Bhaban, Central Jame Masjid Road, Joydebpur, Gazipur.  
Hot Line : 09612668866, Mobile : 01713452238, 01708527419, 01886452240

Invoice No : **23085580**

Patient's Name : Mr. Gopal Chandra Saha

Specimen : Blood

Investigation : Plasma Glucose Random(RBS), CUS(Plasma Glucose Random(RBS)), LIPID PROF Phone :

Ref. By : Prof. Dr. Anwarul Islam Chowdury MBBS MS (Ortho) FICS (USA)

Inv Date: 28-10-2023 Delivery Date : 28/10/2023

Age : 55 yrs Gender : Male

Coll Time: 28/10/2023 12:31:55 PM Name: Azahar



## Biochemical Report



Reports generated by Auto Biochemistry Analyzer Roche Cobas C311

Test Name	Result	Unit	Reference Range
Random Plasma Glucose(RBS)	<b>6.98</b>	mmol/L	< 7.78 mmol/L
CUS:	<b>Nil</b>		
<b>Lipid Profile</b>			
S Cholesterol(Total) (R)	<b>168.0</b>	mg/dl	<200 Desirable, 200 - 239 Borderline, >=240 High > 300 Very High
S Cholesterol(HDL)	<b>35.0</b>	mg/dl	< 40 Low >= 60 High
S Cholesterol(LDL)	<b>124.7</b>	mg/dl	< 100 Optimal 100 - 129 Near or above optimal 130 - 159 Borderline high 160 - 189 High >= 190 Very high
S. Triglycerides	<b>119.0</b>	mg/dl	<150 Normal 150 - 199 Borderline 200 - 499 High >= 500 Very high
Total Cholesterol / HDL Ratio	<b>4.8</b>		< 5.0
LDL / HDL Ratio	<b>3.56</b>		< 3.50

**Md. Mofazzol Hossain**  
D.M.T (Lab. medicine) Dhaka  
Medical Technologist (Lab)  
Radium Diagnostic Center, Gazipur

**Md. Ali Tareq**  
D.M.T (Lab. medicine) Dhaka  
Medical Technologist (Lab)  
Radium Diagnostic Center, Gazipur

**DR. MD MIJANUR RAHMAN**  
MBBS, DCP(BSMMU)  
Consultant Clinical Pathologist  
Uttara Adhunik Medical Collage Hospital



# রেডিয়াম ডায়াগনস্টিক সেন্টার RADIUM DIAGNOSTIC CENTRE

Unit-2 : H-98, Swad Bhaban, Central Jame Masjid Road, Joydebpur, Gazipur.  
Hot Line : 09612668866, Mobile : 01713452238, 01708527419, 01886452240

Invoice No : 23085580

Inv Date: 28-10-2023 Delivery Date : 28/10/2023

Patient's Name : Mr. Gopal Chandra Saha

Age : 55 yrs Gender : Male

Specimen : Blood

Coll Time: 28/10/2023 12:31:59 PM Name: Azahar

Investigation : CRP

Phone :

Ref. By : Prof. Dr. Anwarul Islam Chowdury MBBS MS (Ortho) FICS (USA)



## Serological Report



Reports generated by Auto Hipro-Hurricane (HP-083/4-II)

Test Name	Result	Unit	Reference Range
-----------	--------	------	-----------------

**CRP(Q+Q)**

Sample Value :

2.5

mg/l

< 10.0 mg/l is Negative  
> 10.0 mg/l is Positive

Opinion :

Negative ( -ve)

**Md. Mofazzol Hossain**  
D.M.T (Lab. medicine) Dhaka  
Medical Technologist (Lab)  
Radium Diagnostic Center, Gazipur

**Md. Ali Tareq**  
D.M.T (Lab. medicine) Dhaka  
Medical Technologist (Lab)  
Radium Diagnostic Center, Gazipur

**DR. MD. MIJANUR RAHMAN**  
MBBS, DCP(BSMMU)  
Consultant Clinical Pathologist  
Uttara Adhunik Medical Collage Hospital

Printed By: Kanai





# রেডিয়াম ডায়াগনস্টিক সেন্টার RADIUM DIAGNOSTIC CENTRE

Unit-2 : H-98, Swad Bhaban, Central Jame Masjid Road, Joydebpur, Gazipur.  
Hot Line : 09612668866, Mobile : 01713452238, 01708527419, 01886452240

## X-RAY REPORT

Patients Name	Mr.Gopal Chandra Saha	Age : 55 yrs
Ref. By Dr/Prof	Prof. Dr. Anwarul Islam Chowdury MBBS MS (Ortho) FICS (USA)	
Name of X-Ray	X-RAY RT KNEE JOINT B/V (Digital)	
Film No.	23085580	Date : 28/10/2023

Osteophytes are seen in the posterior surface of patella, condyles of femur & tibia.

Joint spaces appear normal.

Soft tissue shadow is unremarkable

**Impression: Early osteo-arthritis**

**DR. MD. BORHAN UDDIN**

MBBS, BCS

M. Phil, MD (Radiology & imaging)

Asst.Professor & Head of the Dept (Radiology)

**Kurmitola General Hospital, Dhaka.**