

Nasreen Sultan 5346

Dr. Wakil Ahmed. 05/08/23

LBR

OA with knee

rx

DM (+)

HTN (+)

Cap. segeel, 20mg

2000 + 1000 (1000)

⊗ / TB, Renova x2 / Napador
2000 + 1000 (1000)
(1000)

Cap. Neobion

2000 - 1000

Cap. Pregbasol

2000 - 1000

Cap. Osteo D

2000 - 1000

Cap. Osteo D (+)

(cap x 1/2 1000 1000)

1000 x 1000 1000

Neopenem®
meropenem USP



08.10.23

Col. Inert 2-up

1000 + 6000

(10)



24.09.23

long X-ray (L) knee AP/lat
standing & skyline view



BIOCHEMISTRY REPORT



Invoice No : 123262069	Invoice Date : 24/07/23	Delivery Date : 24/07/23	Report No : 12307876861
Patient Name : MRS. NASRIN SULTANA	Age : 52Y	Gender : Female	
Referred By : SELF			
Sample : SERUM	LAB. No : 12307957330		
Tests : RA/RF			

Test is carried out by Beckman Coulter AU480

Test	Result	Reference Value
RA/RF	1.30 IU/mL	Upto 14.0 IU/mL



HN :


288

Report Status : Final

Powered by: MYSOFT Ltd.

Prepared by:
Ms. Ruma
Computer Operator


Verified by:
Biochemist


PROF. DR. MD. HUMAYUN KABIR
MBBS (DMC), M. Phil (Microbiology),
Dept. Of. G. Pathology and Microbiology,
Dhaka Dental College, Dhaka

Print by & Date :: RUMA on 24/07/2023 03:53:50 PM

Page 1 of 1

Pain, Paralysis & Physiotherapy Specialist
Associate Professor Dr. S Chakrovorty (PT)



Chamber:

**Specialized Physiotherapy
& Arthritis Research Center Ltd.**



PhD (Scholar) JUST
BPT (DU), MPT (DU), MPH (DIU)
Osteopath (OCO, Canada)
Neurodynamics (NDS, Australia), MDMR-BOU;
Special Training in MDT (UK)
TMS (Brain Stroke), University College of London
Ex Physiotherapist, National Team,
Bangladesh Cricket Board & CRP
Founder & President-BPA

Associate Professor

Dhaka College Of Physiotherapy

Affiliated of Dhaka University

Chairman

S P Hospital.

Mobile: 01793 557 825

Mrs. Nasrin Sultana

Age: 53 years

Date: 01-05-2023

Patient's Name: Mrs. Nasrin Sultana

Complaints

PT. RECORD

- Pain in back refer to both lower limbs. During walking increase pain and heaviness..... 5 years

Diagnosis

- PLID
- OA

Treatments

- physiotherapy with of 3-4 wks
- Back Extension Exercise
- Leg stretching and Strengthening exercise
- L/T 10 minutes
- TENS
- IRR
- WAX
- UST
- Used lumber corset belt.

Advice

- MRI OF Lumbosacral spine lateral view full spine.
- BMD FULL SPINE
- USG of W/A

Cap- joints starts banno
at ulbon starts for
Aschubel
type he waley ulbon
jante gel mmm

23
[Signature]

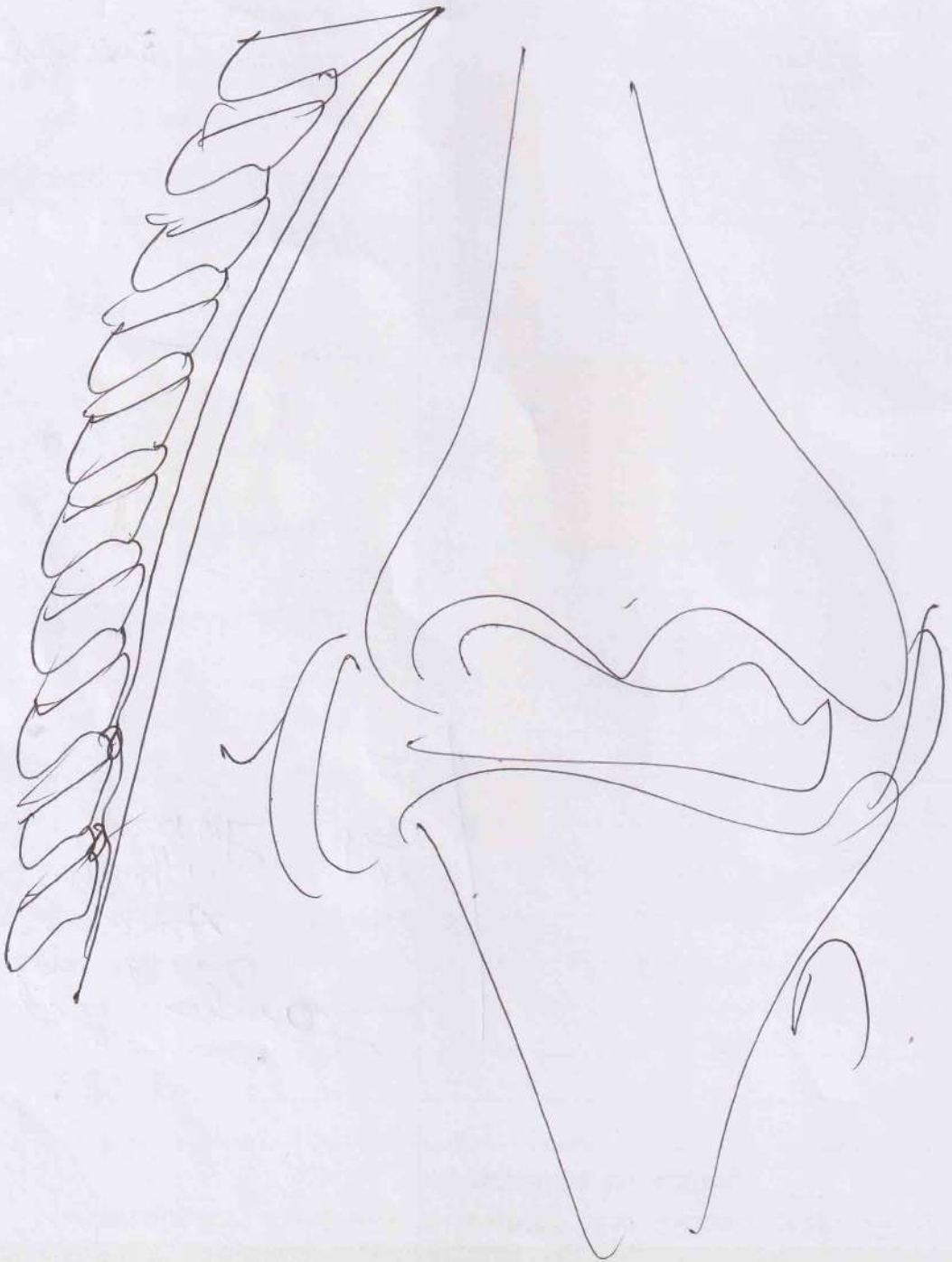
..... দিন/মাস পর আবার আসবেন।

বিঃ দ্রঃ পরবর্তী সাক্ষাতের সময় এই ব্যবস্থাপত্র অবশ্যই সঙ্গে নিয়ে আসবেন।

বাড়ী নং- ৩২-৩৫, প্রবাল হাউজিং, শ্যামলী, রিং রোড, আদাবর, ঢাকা-১২১৭

ফোন : ৮১৪২১৮৪, ৮১৪২১৮৩, মোবাইল : ০১৭১১-৬৮২৭৭১, ০১৭১২-২৮৩৪৮৪ E-mail: sphddhaka@gmail.com

Applied Psychophysiology
Psychophysiology Research Center, Ltd.



DEPARTMENT OF RADIOLOGY & IMAGING

ID. No.	20759	Age	53Y	Sex	F
Patient Name	MRS.NASRIN SULTANA				
Order Time	01/05/2023 08:46	Report Time	02/05/2023 12:40		
Referred by	SPARC				

MRI of Lumbo-sacral Spine with screening of whole spine

Thank you for the courtesy of this kind referral

- Protocol: Sagittal - SE T1, FSE T2. Axial - SE T1, GE T2.
- Clinical information: H/O. Low back pain.

Findings:

- Lumbar lordosis is maintained with normal vertebral alignment.
- On T2 weighted images lumbar discs are hypointense due to desiccation.
- The bone marrow of the vertebral bodies appears normal.
- The articulating vertebral end plates present smooth margins.
- The conus medullaris terminates normally at the L1 level and divides into its filaments.
- Visualized part of the cord appears normal in signal characteristics and morphology.
- Imaged pre and paravertebral soft tissue appear normal.
- **At L4-5 & L5-S1 level:** Circumferential disc bulge causing anterior indentation of the thecal sac without neural compromise.



House 32/35, Probal Housing Ring Tower Land Mark,
Ring Road, Adabor, Dhaka-1207
Mobile: 01712 283484
N.P. Appointment:- 01711 682771, 8142184, 8142183

E-mail: sphddkaka@gmail.com
Website: www.sparcbd.com

SPAR**S P HOSPITAL & DIAGNOSTIC LAB****Specialized Physiotherapy Arthritis Research Center Ltd.****DEPARTMENT OF RADIOLOGY & IMAGING**

ID. No.	20759	Age	53Y	Sex	F
Patient Name	MRS.NASRIN SULTANA				
Order Time	01/05/2023 08:46	Report Time	02/05/2023 12:40		
Referred by	SPARC				

Impression:

- Degenerative disc disease.
- **At L4-5 & L5-S1 level:** Circumferential disc bulge causing anterior indentation of the thecal sac without neural compromise.

N.B: Screening of rest of the spine showing –

- Disc bulge at multiple cervical and dorsal levels.
- Degenerative disc disease.

Reported by Electronic Signature

Afroza

Dr. Afroza Akhter

MBBS, MD (Radiology & Imaging).

Radiologist

CT scan & MRI Specialist

Shaheed Suhrawardy Medical College & Hospital

BMDC Reg No: 52453

Mobile: 01743605621

Mirza

Checked by Medical Technologist



House 32/35, Probal Housing Ring Tower Land Mark,
Ring Road, Adabor, Dhaka-1207
Mobile: 01712 283484
N.P. Appointment:- 01711 682771, 8142184, 8142183

E-mail: sphddkaka@gmail.com
Website: www.sparcbd.com