



Subhanighat, Sylhet, Bangladesh
Email: oasis-hospitals@gmail.com
Helpline: 01611-99 00 00, 0821-729122-23

Md. Billal Humsain Rony, 23 year, who has been suffering from headache, palpitation, nasal bleeding, unconsciousness (occasionally) for 3 years. He visited multiple neuro medicine specialist in Bangladesh. They advised him to go India for better treatment. That's why, he want to go India for better treatment.

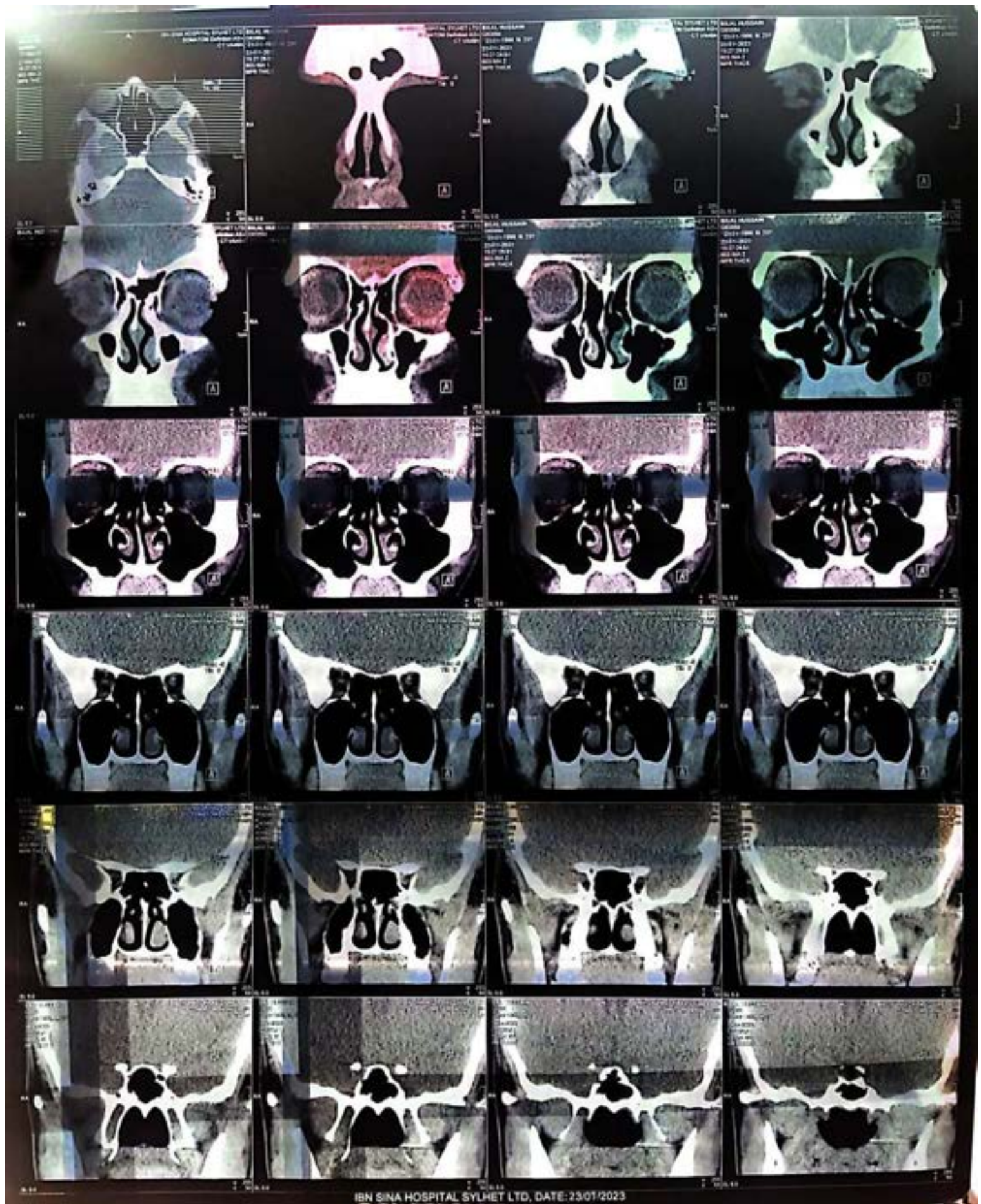
(N.B- All investigation and file are attested)

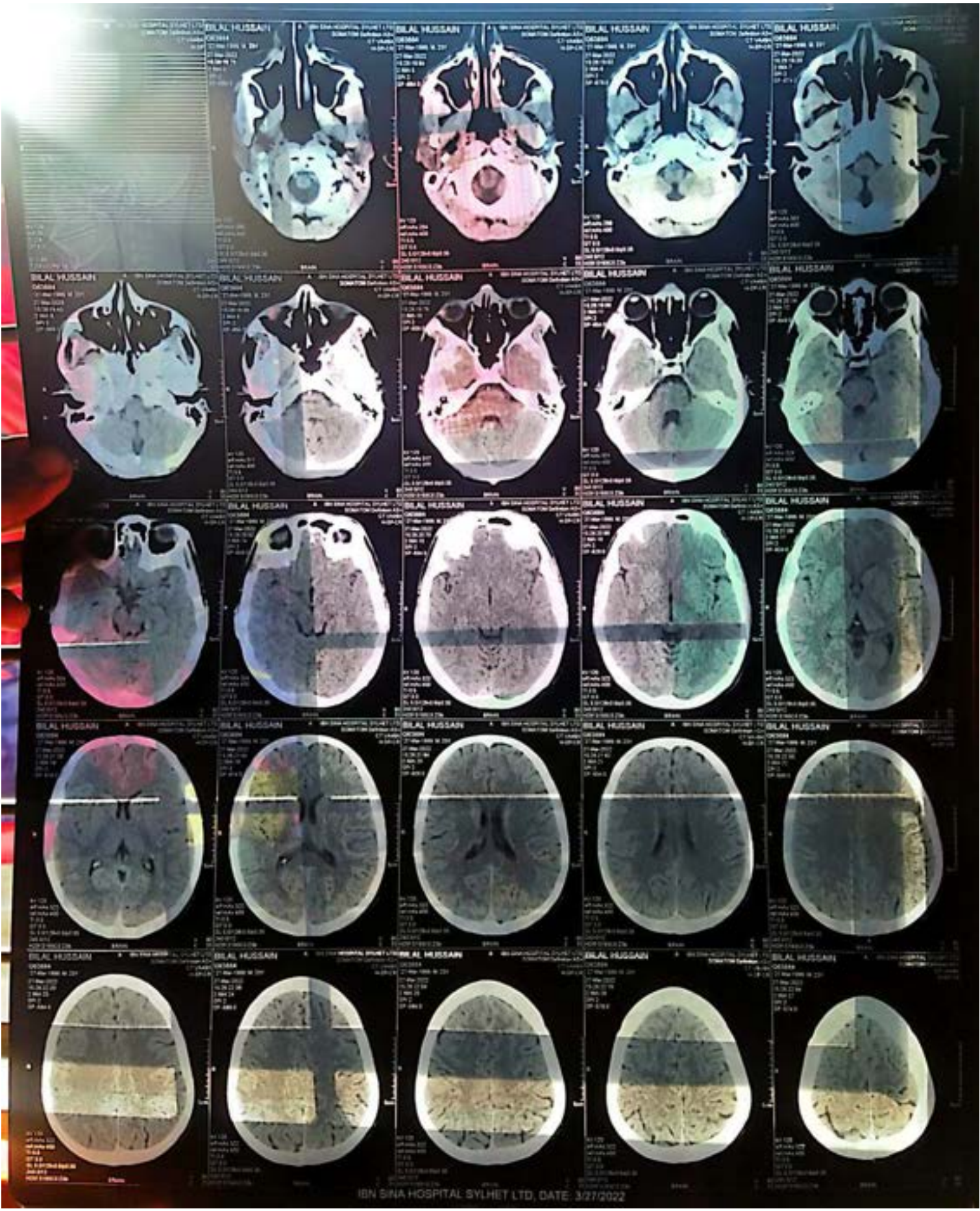
Yours sincerely

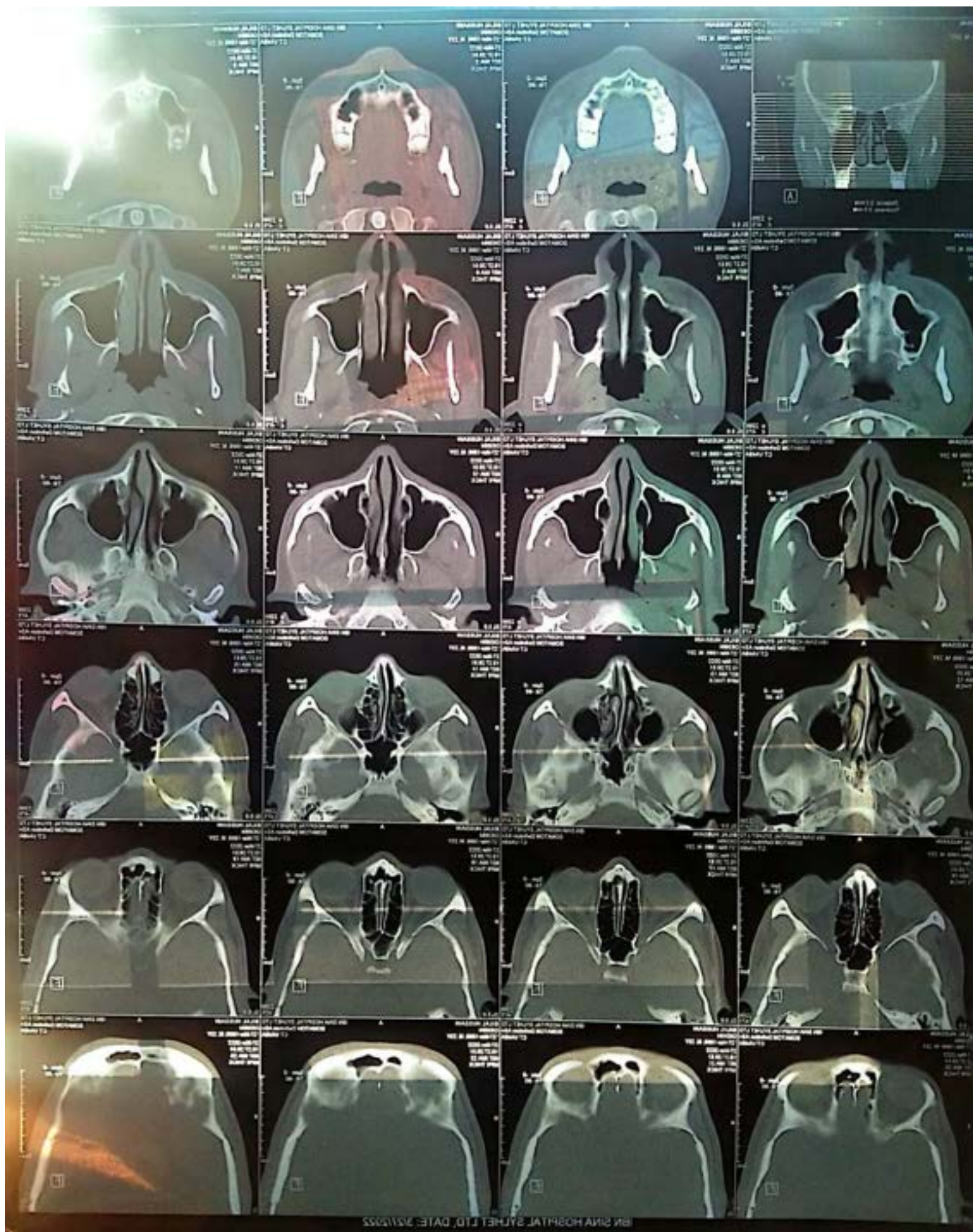
Medical Officer (Emergency department)


Oasis Hospital, Sylhet.

17.06.2023
Emergency Medical Officer
Oasis Hospital, Sylhet.









ডাঃ মোফাখখারুল ইসলাম

এম,বি,বি,এস; ডি,এল,ও; এমসিপিএস (ই,এন,টি)
 নাক, কান, গলা রোগ বিশেষজ্ঞ ও
 হেড-নেক সার্জন
 বি.এম.ডি.সি. রেজি. নং- A-34803



Office



DR. MD. MOFAKKARUL ISLAM
 Assistant Professor,
 Department ENT & Head-Neck Surgery
 Jalalabad Rogib - Rabeya Medical
 College & Hospital, Sylhet Bangladesh
 Email: jrmcinfo@gmail.com
 Email: mmislamjmc@gmail.com

Special interest in skull base surgery

Name: Mr. Bilal Hussain Age: 20/2/24 Date: 23/01/2023

GE

1. Rec. epistaxis

PE

Ear

Nose

Throat

Naso-Endoscopy done

- (NM)

(NM)

1 Primary Epistaxis
 (↓ evaluation)

2.

3. Rocal - 0-vita - 1ph

1-0-01 ২২৫

(১নম্বর সার্জিকাল রিপোর্ট)

4. 3. Tenil 20mg - 10

0-১২ ১২-০৫

5. 3. Rofecelaw 250mg

1-0-01 ৭ঘন্টা - ৪

৪/৩/২০২২

6. 3. Vitalgin

2-১২০ x 2২০

(NM) - 1ph

এডভান্সডিক
 মাইক্রোসার্জারী ও
 হেড-নেক ক্যান্সার সার্জারী
 বিশেষজ্ঞ

ফেলোশীপ ইন ট্রিনিম্যাল অটোলজি (পুনে, ইন্ডিয়া)
 ফেলোশীপ ইন রাইনোলজি (সিউল, কোরিয়া)
 ফেলোশীপ ইন এডভান্সডিক অফ বেইজ
 সার্জারী (তাইপে, তাইওয়ান)



IBN SINA

Pioneer in Health Care

• Sobhanighat Sylhet

• Tel : 0821-727933-42

• Hotline : 09636-300300

• E-mail : info@ibnsinahospitalssylhet.com.bd

• Web : ibnsinahospitalssylhet.com.bd

IBN SINA HOSPITAL SYLHET LTD.

COMPUTED TOMOGRAPHY REPORT

ID. No.	: Q63884	Receive: 01.23, 2023 03:05 PM	Print: 01.26, 2023 06:27 PM
Patient's Name	: MR BILAL HUSSAIN		
Age	: 23 year(s)	Sex	: Male
Refd. by	ASST.PROF.DR.MD MOFAKKARUL ISLAM. MBBS. DLO.MCPS		

CT SCAN OF PNS

Clinical information:

H/O Recurrent epistaxis

Sequences:

Multi axial non-contrast CT scan was performed.

Findings:

Frontal sinus : Normal in size. Single septa present. No mucosal thickening or mass lesion seen.

Maxillary sinus : Normal in size. No septation or mucosal thickening or mass lesion seen.

Sphenoidal sinus : Normal in size. No septation or mucosal thickening or mass lesion seen.

Ethmoidal sinus : Air cells are normal in size. No opacifications seen. Osteomeatal units appear normal.


Nasal septum : Deviated convexity towards right side.


Both the inferior turbinate are mildly hypertrophied.

Middle turbinates appear normal.

Ethmoidal roof, anterior cranial fossa appear normal.

Comment: DNS with bilateral HIT.


Prof. Dr. Mostaque Ahmed Bhuiyan
MBBS, MD (BSMMU), FCPS.
Advanced training on CT & MRI
(India, Singapore, USA)
Consultant Radiology & Imaging
Ibn Sina Hospital Sylhet Ltd.


Dr. Swajal C. Das
MBBS, MD (DU)
Special training on CT, MRI
Consultant Radiology & Imaging
Ibn Sina Hospital Sylhet Ltd.

COMPUTED TOMOGRAPHY REPORT

ID. No.	: Q63884	Receive: 01.23.2023 03.05 PM	Print: 01.26.2023 06.27 PM
Patient's Name	: MR BILAL HUSSAIN		
Age	: 23 year(s)	Sex	: Male
Refd. by	: ASST.PROF.DR.MD MOFAKKARUL ISLAM. MBBS. DLO.MCPS		

CT SCAN OF BRAIN

Clinical information:

H/O Headache.


Sequences:

Multislice volumetric non-contrast CT scan was performed.

Findings:

No obvious focal lesion is seen in the brain.
 Midline structures are not shifted.
 Ventricles and extraventricular CSF spaces are unremarkable.
 Brainstem and cerebellum appear normal.
 C-P angles are unremarkable.
 Sella & parasellar areas are normal.
 Orbit and retro-orbital soft tissues appear normal.

Comment: No significant abnormality detected in brain.



Prof. Dr. Mostaque Ahmed Bhuiyan
 MBBS, MD (BSMMU), FCPS.
 Advanced training on CT & MRI
 (India, Singapore, USA)
 Consultant Radiology & Imaging
 Ibn Sina Hospital Sylhet Ltd.



Dr. Swajal C. Das
 MBBS, MD (DU)
 Special training on CT, MRI
 Advanced training on MRI- Mumbai (India)
 Consultant Radiology & Imaging
 Ibn Sina Hospital Sylhet Ltd.

ডাঃ কামাল আহমদ

এমবিবিএস, এফসিপিএস (মেডিসিন), এমডি (নিউরোলজি)
অধ্যাপক, নিউরোলজি বিভাগ
নর্থ ইস্ট মেডিকেল কলেজ হাসপাতাল, সিলেট।

নিউরোলজি ও মেডিসিন বিশেষজ্ঞ



DR. KAMAL AHMED

MBBS, FCPS (Medicine), MD (Neurology)
Professor, Neurology Department
North East Medical College Hospital, Sylhet

Md. Billal Hasan Rony, 23 Y



Visit No : 1 Date : 26-03-2023

History:

Headache
LOC - Recurrent

Important Info:

USWA- NAD
CBC - NAD
Echo (2D) - NAD

O/E:

BP:(supine) 100/70 mm Hg;

Diagnosis:

TTH

Pseudo seizure disorder ?

Rx

1. Tab. Clonium 0.5 mg (Clonazepam) - 10
১ টা করে রাতে শোয়ার সময় - ২ মাস। (রাত্রে ৯.০০ টায়)
2. Tab. Fluver 5 mg (Flunarizine) - 14
১ টা করে দিনে ২ বার - ২ মাস।
3. Tab. Indever 40 mg (Propranolol HCl) -
অর্ধেক টা করে দিনে ২ বার - চলবে।
4. Tab. Maxpro 20 mg (Esomeprazole) - 14
১ টা করে দিনে ২ বার (আহারের আগে) - ২ মাস।
5. Tab. Solas 100 mg (Mebendazole)
১ টা করে ২ বার - ৩ দিন।

Advice :

স্বাভাবিক সব খাবার খাবেন।

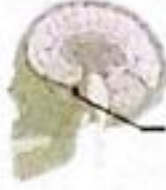ঘটনার ভিডিও করবেন।

← ৩ মাস পরে আবার আসবেন।

Dr Kamal Ahmed

ডাঃ খান আসাদুজ্জামান

এমবিবিএস, এমআরসিএস (ইউ.কে), এফআরসিএস (গ্র্যাসগো)
ফেলো ইন পেইন ম্যানেজমেন্ট, দিল্লি, ইন্ডিয়া।
প্রাক্তন নিউরো-সার্জারী বিশেষজ্ঞ, এ্যাপোলো হাসপাতাল, ঢাকা।
কিং ফাহাদ হাসপাতাল, সৌদি আরব।
ব্রেইন, নার্ভ, মেরুদণ্ড ও ক্রনিক পেইন বিশেষজ্ঞ
বিভাগীয় প্রধান, নিউরোসার্জারী বিভাগ
নর্থ ইস্ট মেডিকেল কলেজ ও হাসপাতাল, সিলেট।
বিএমডিসি রেজিঃ নং- এ-২৪৭০১



Dr. Khan Asaduzzaman

MBBS, MRCS (UK), FRCS (Glasgow)
Fellow in pain management, Delhi, India.
Ex. Neurosurgeon, Apollo Hospital, Dhaka.
King Fahad Hospital, Saudi Arab.
Brain, Nerve, Spine & Chronic Pain Specialist
Head, Department of Neurosurgery
North East Medical Collage & Hospital, Sylhet.
BMDC Reg. No. A-24701

নাম : MD Billal Hossain বয়স: ওজন: 23 তারিখ: 11/9/23

C/c:

Hand bleeds?
Headache,
no deficit.

Rx

Tu Topiram 250
1 to 1 - 3 mt.
1 Tu indover 100
1 to 1 - 3 mt.

Advice:

CT scan brain
PNS

11/9/23



চেয়ার : পপুলার মেডিকেল সেন্টার এন্ড হাসপাতাল সিলেট, সোবহানীঘাট, সিলেট। ফোন নং- ৩৫৭ (৩য় তলা)
রোগী দেখবেন: বিকাল ৪টা থেকে সন্ধ্যা ৬টা পর্যন্ত (বৃহস্পতি ও শুক্রবার বন্ধ)। সিরিয়াল, তথ্য ও অনুসন্ধান: ০৯৬০৬৭৭২২১১



HAEMATOLOGY REPORT

Invoice No : 122064592 Invoice Date : 30/05/22 Delivery Date : 31/05/22 Report No : 12205212230
 Patient Name : MR. BILLAL Age : 23Y Gender : Male
 Referred By : PROF. (DR) A. K. M. MUSA MBBS, FCPS, MCPS, DTCO

Sample : BLOOD LAB. No : 12205237036
 Tests : CBC

Test is carried out by Starrsed RS, Sysmex XN 1000

Exam Name	Result	Normal Range		
Haemoglobin	13.6 g/dL	Male: 15 ± 2 g/dL Female: 13.5 ± 1.5 g/dL 1 Yr: 12.6 ± 1.5 g/dL, 2-6 Yrs: 12.5 ± 1.5 g/dL 6-12 Yrs: 13.5 ± 2 g/dL		
ESR (Westergren Method)	2 mm in 1st hour	Male: Upto 10 mm in 1st hour Female: Upto 15 mm in 1st hour		
Total Count				
White Blood Cells	6.20 K/ μ L	4.00 - 11.00 K/ μ L		
Red Blood Cells	5.39 M/ μ L	Male : 5.0 ± 0.5 M/ μ L Female : 4.3 ± 0.5 M/ μ L		
Platelets	261 K/ μ L	150 - 450 K/ μ L		
Differential Leucocyte Count				
	%	Absolute	%	Absolute
Neutrophil	51 %	3.16 K/ μ L	40 - 75 %	2.0 - 7.0 K/ μ L
Lymphocyte	43 %	2.67 K/ μ L	20 - 40 %	1.5 - 4.0 K/ μ L
Monocyte	04 %	0.25 K/ μ L	02-10 %	0.2 - 1.0 K/ μ L
Eosinophil	02 %	0.12 K/ μ L	01-06 %	0.02 - 0.50 K/ μ L
Basophil	00 %	0 K/ μ L	<01 %	0.02 - 0.10 K/ μ L
Others				
CT	42.1 %		Male: 45 ± 5 % Female: 41 ± 5 %	
MCV	78.1 fL		78.0-98.0 fL	
MCH	25.2 pg		27.0-32.0 pg	
MCHC	32.3 g/dL		30 - 35 g/dL	
RDW-CV	12.9 %		11.60 - 14.60 %	
RDW-SD	36.6 fL		39.0 - 46.0 fL	
MPV	9.9 fL		7.20 - 9.20 fL	
P-LCR	24.0 %			
nRBC	0.2 /100 WBC			

Blood Film : RBCs show hypochromia ,microcytosis with some elongated cells.
 WBCs are mature with above count & distribution.
 Platelets are adequate.
 Comment: Microcytic hypochromic blood picture.
 Advice: Haemoglobin electrophoresis.

Prepared by:
 Ms. Ruma
 Computer Operator

Verified by:
 Medical Technologist

ASSOC. PROF. DR. MOHAMMAD ALI
 MBBS, FCPS (Haematology)
 Department of Haematology,
 National Institute of Cancer
 Research & Hospital
 Mohakhali, Dhaka.

Print by & Date :: saif on 30/05/2022 08:06:06 PM



BIOCHEMISTRY REPORT



Case No : 122064592 Invoice Date : 30/05/22 Delivery Date : 31/05/22 Report No : 12205212218
 Patient Name : MR. BILLAL Age : 23Y Gender : Male
 Referred By : PROF. (DR) A. K. M. MUSA MBBS, FCPS, MCPS, DTCD

Specimen : SERUM LAB. No : 12205237037
 Test : Electrolytes Serum

Test is carried out by Beckman Coulter AU480

Test	Result	Reference Value
Electrolytes		
Sodium (Na ⁺)	138.77 mmol/L	136-145 mmol/L
Potassium (K ⁺)	3.90 mmol/L	3.5-5.1 mmol/L
Chloride (Cl ⁻)	102.75 mmol/L	98-107 mmol/L
Carbon dioxide (Co ₂)	24.6 mmol/L	Adult 22-30 mmol/L Child- 18-24 mmol/L
Bi-Carbonate (HCO ₃)	23.3 mmol/L	Adult 22-29 mmol/L Child- 17-23 mmol/L

Verified by:

Name

Signature Operator

Verified by:

Medical Technologist

Prof. Dr. Md. Abdur Rahman
 MBBS.M.Phil (Microbiology)
 Head of the department
 Pathology & Microbiology
 Dhaka Dental College, Dhaka.

Print Date :: RUMA on 30/05/2022 08:49:00 PM

Page 1 of 1

Address: Dhaka

Plot No: 92, Road # 2

Phone No: 02-48033802

Mobile: 01769960455-56



Aalok (Mirpur-11)

27 Durga Suktan Road

Mirpur-11, Dhaka

Phone: 02-48033802

Mobile: 01761448300



Aalok (Paltan): Mirpur-11

24 Paltan, Mirpur, Dhaka-1216

Phone: 02-48033802, 01825912667

www.aalokhealthcare.com



Aalok (KochuKhet)

Rajshahi Tower (4th & 5th Fl)

Mirpur-11, Dhaka

Phone: 02-9711512, 01725695669

Mobile: 01846116600@gmail.com



Aalok (Ghata)

Empal, Bangladesh

Phone: 01769969961

Mobile: 01769969969



Aalok (KAWC)

Mohakhali Health

Complex, Mohakhali,

Dhaka. Phone: 01769969962



IMMUNOLOGY REPORT



Invoice No : 122064592 Invoice Date : 30/05/22 Delivery Date : 31/05/22 Report No : 12205212249
 Patient Name : MR. BILLAL Age : 23Y Gender : Male
 Ordered By : PROF. (DR) A. K. M. MUSA MBBS, FCPS, MCPS, DTCD
 Sample Type : SERUM LAB. No : 12205237038
 Test Name : TSH

Test is carried out by Architect Plus I1000 SR

Test	Result	Reference Value
TSH	0.67 μ IU/mL	Adult: 0.350-5.50 μ IU/ml Newborn : 1.0-25 μ IU/ml Infants: 0.8-9.10 μ IU/ml Children: 0.7-5.70 μ IU/ml

Ordered by:
 Patient Name:
 Operator

Verified by:
 Medical Technologist

Prof. Dr. Md. Abdur Rahman
 MBBS, M.Phil (Microbiology)
 Head of the department
 Pathology & Microbiology
 Dhaka Dental College, Dhaka.

Printed & Date :: RUMA on 30/05/2022 08:48:56 PM



USG REPORT



Invoice No : 122064592	Invoice Date : 30/05/2022	Delivery Date : 31/05/2022	Report No. : 12205064775
Patient Name : MR. BILLAL	Age : 23Y	Gender : M	
Ref. Doctor : PROF. (DR) A. K. M. MUSA MBBS, FCPS, MCPS, DTCD			
Test Name : USG OF WHOLE ABDOMEN			

Examination done in 4D USG (Voluson E10) machine, GE Healthcare.

Thank you for your kind referral

THE LIVER:

The liver is normal in size (about 14.0 cm). Parenchymal echogenicity is reduced with prominent peri portal echoes. No focal lesion is seen.

THE GALL BLADDER:

The gall bladder is normal in size & wall thickness. No intraluminal biliary sludge, mass lesion or calculus is seen.

BILIARY TREE:

Biliary channels are not dilated. No mass or calculus could be detected.

THE PANCREAS:

The pancreas is normal in size and echopattern. No focal lesion is noted. MPD is not dilated.

THE SPLEEN:

The spleen is normal in size (about 10.21 cm) with homogeneous echopattern. No focal lesion is seen. Vascular dilatation is not present in hilar region.

P.T.O



ID- 122064592

KIDNEYS:

Both kidneys are normal in size (RK 10.04 cm bipolar x 3.64 cm A/P diameter, LK 9.90 cm bipolar x 3.94 cm A/P diameter) & position with well defined cortex and medulla. Pelvicalyceal systems of both are not dilated. No mass or calculus could be detected.

THE URINARY BLADDER:

The urinary bladder is well filled with regular in outline. No intravesical mass lesion or calculus is seen.

PROSTATE:

The prostate is normal in size (2.53 cm x 2.90 cm x 3.05 cm) and normal in echopattern. Volume measures about 11.71 cc.


No ascites, pleural effusion or intra abdominal lymphadenopathy is seen.

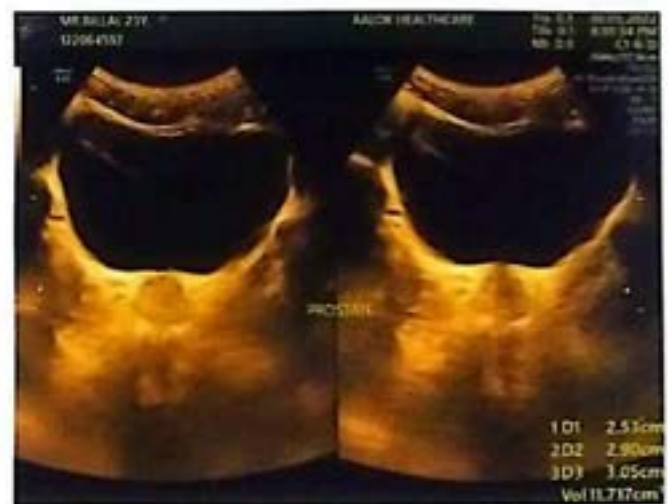
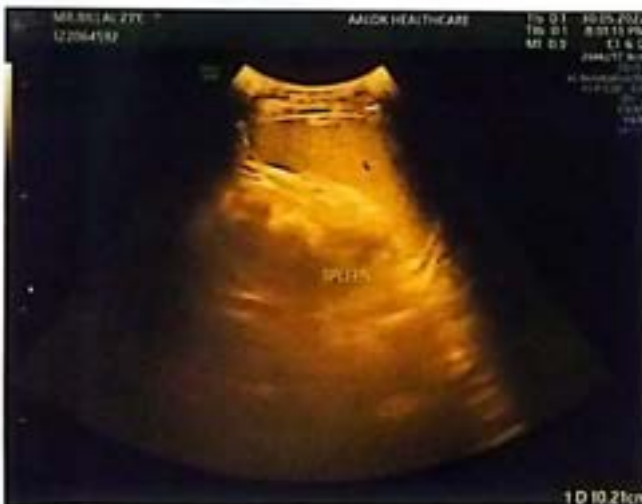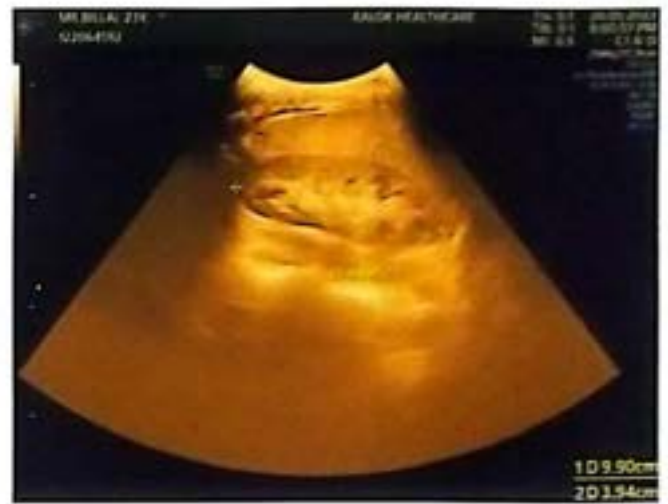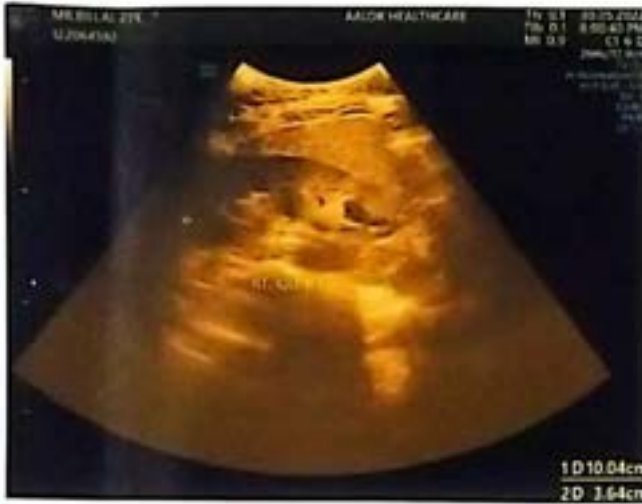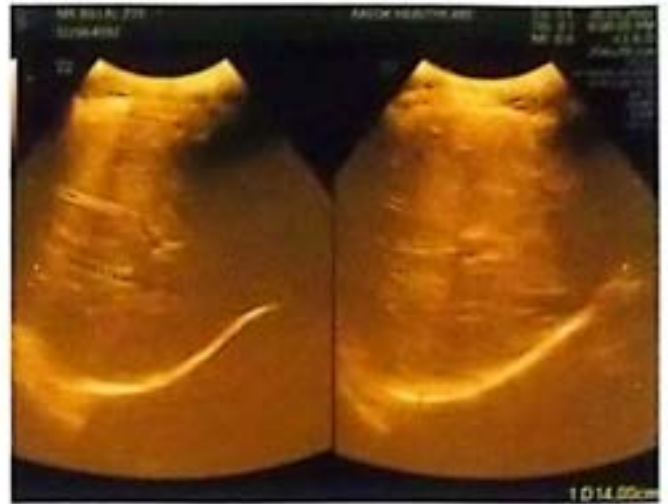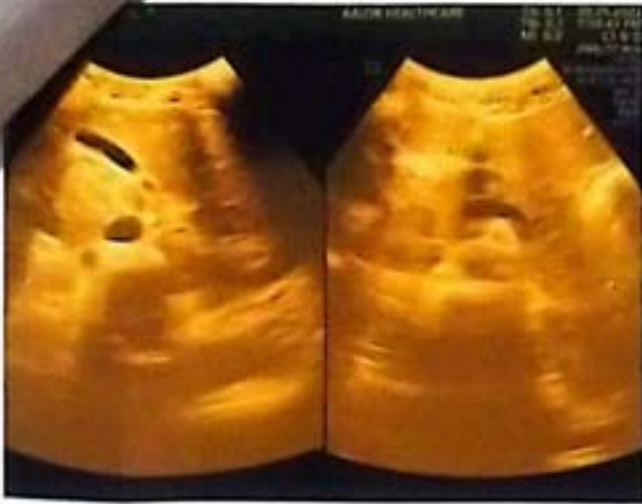IMPRESSION: Suggestive of acute hepatitis.

Advice: LFT correlation for further evaluation.

Prepared By ::

Mrs. Sabera

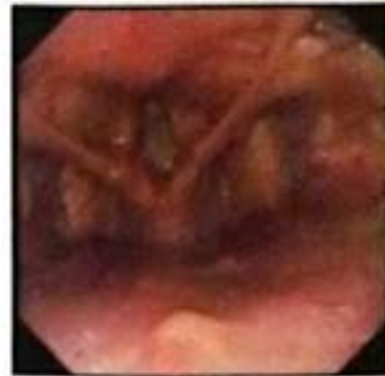
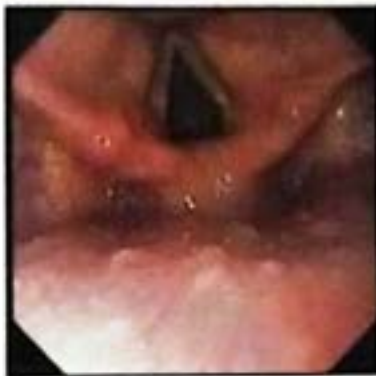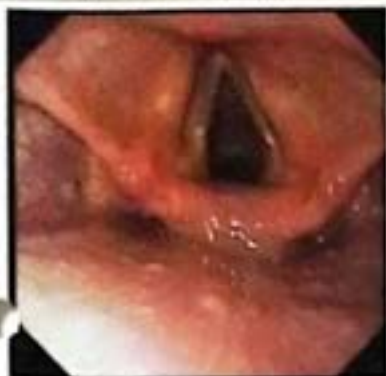DR. JAHANARA LAIZU
MBBS, BCS, M. Phil (Nuclear Medicine)
Assistant Professor (Nuclear Medicine)
Dept. of Radiology & Imaging,
National Institute of Kidney Disease &
Urology (NIKDU), Dhaka





Identity No.	122064592	Visit Date	31 May, 2022
Patient Name	MR. BILLAL	Age / Sex	23 / Male
History	N/A	Instrument	Olympus CV-150
Referrer	PROF. (DR) A. K. M. MUSA, MBBS, FCPS, MCPBeBTCD		OPD

ENDOSCOPIC PROCEDURE REPORT



Procedure : FOL

Indication : N/A

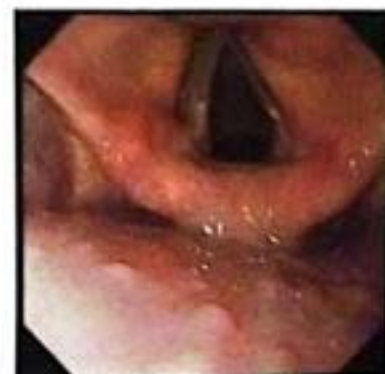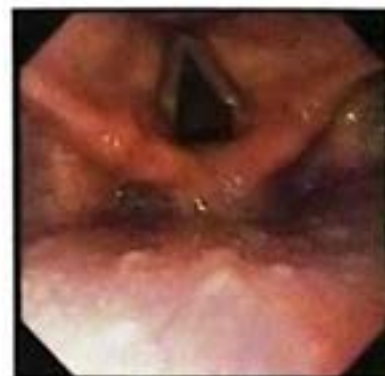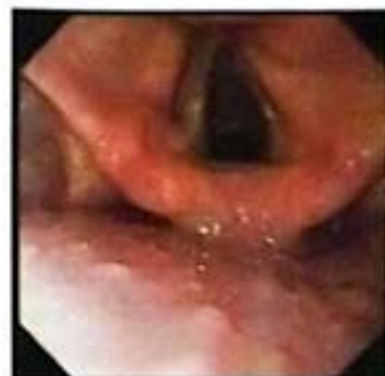Medication : 10% Lidocaine spray

FINDINGS :

Hypopharynx: Normal

Larynx: Both the piriform fossa, vocal cords and aryepiglottic folds are normal. The movement of both vocal cords are normal with respiration and phonation. Epiglottis is normal. Vallecula, base of the tongue and uvula are also normal.

COMMENTS : Normal FOL



Nazmul Hoque
Assoc Prof. Dr. Md. Nazmul Hoque
MBBS, MD(Gastro)
(EX) ASSOCIATE PROF & HEAD,
DEPT OF GHPD, BIRDEM HOSPITAL

DR. MD. ABDUL GHANI

MBBS (CU), D.Card (BSMMU)

ASSOCIATE PROFESSOR

Department of Cardiology

North East Medical College & Hospital Sylhet.

BMDC Reg. No. A 18060

**HEART SPECIALIST**

Trained in INTERNAL MEDICINE

Trained in ADULT CARDIOLOGY

Trained in PEDIATRIC CARDIOLOGY

(Karala, Hyderabad, India)

Ex. Senior Registrar and Cardiologist

Apollo Hospitals, Dhaka

01711300381

Md. Billal Hussain Rony, 23 Y



2107267473

Visit No : 1

Date : 26/07/2021

History:

chest pain + palpitation - 5 yrs - more for 1 month - on anxiety - NOT EXERTIONAL.

blood stained vomiting - VERY OCCASSIONAL.

lost consciousness during sleep - two events - in 5 yrs period.

O/E:

Pulse: ~64/min,

Erect:130/80 mm Hg;

S1 S2 M0

Clear lungs.

carotid bruit NONE.

Diagnosis:

AN.

Dyspepsia.

?? Epilepsy : Adv. Neuro consultation.

Rx

1. Tab. Angenta 0.5 mg+10 mg (Flupentixol + Melitracen)
1 + 0 + 0 - ২ মাস
2. Tab. Folic Acid 5 mg (Folic acid)
1 + 0 + 0 - চলবে।
3. Tab. Paricel 20 mg (Rabeprazole Sodium)
1 + 0 + 1 (আহারের আগে) - ২ মাস।
4. Tab. Omidon 10 mg (Domperidone)
1 + 1 + 1 - ১ মাস - ব্যাপ্তার ১/২ ঘণ্টা আগে।
5. Tab. Erata 250 mg (Lamotrigine)
½ + 0 + ½ - ৫ দিন; তারপর ১ + ১ + ১ - চলবে।

✓ 6. Symp. Novelta
2+2+2 ডায়ট x ২ সপ্তাহ
ব্যাপ্তার ১/২ ঘণ্টা আগে।

Phew
26/7/21

Tests Advised:

- ✓ 1. ECG (Electrocardiogram)
- ✓ 2. ECHO SCREENING

✓ Referred To NEUROLOGY CONSULTATION for ? epileptic fit during sleep.

Adv

✓ USG of whole abdomen (N)

✓ CBC (OK)

চেয়ার : সিলেট মা ও শিশু হাসপাতাল

উপকণ্ঠ আ/এ, সোবহানীঘাট, সিলেট।

সাক্ষাতের সময়: বিকাল ৩টা থেকে সন্ধ্যা ৬টা পর্যন্ত।

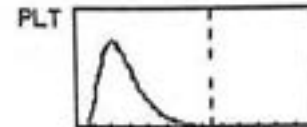

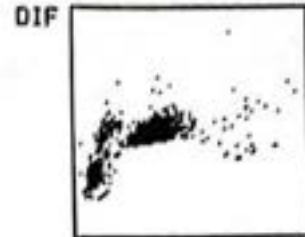
সিরিয়ালের জন্য : ০১৭৩০-৮৫৮৮৩৩, (শুক্রবার বন্ধ)।

Name :	Patient ID :
Comments : Mr. Bilal Hussain Roy	Sample ID : 48884
	Type : STANDARD

Operator ID :

Date : 28/07/2020 04:47:19PM Seq : 00026

	Result	Flags	Unit
WBC	8.7	*	10 ³ /μL
NEU%	68.3	*	%
LYM%	30.1	*	%
MON%	0.4	*L	%
EOS%	0.8	*L	%
BAS%	0.4	*	%
NEU	5.9	*	10 ³ /μL
LYM	2.6	*	10 ³ /μL
MON	0.0	*L	10 ³ /μL
EOS	0.1	*	10 ³ /μL
BAS	0.0	*	10 ³ /μL
RBC	5.64		10 ⁶ /μL
HGB	14.2		g/dL
HCT	45.0		%
MCV	79.8		fL
MCH	25.2	l	pg
MCHC	31.6		g/dL
RDW	13.9		%
PLT	290		10 ³ /μL
MPV	7.9		fL



It is Machine use
Final and Consultant Sign
Will be Provide as soon as Possible

DR. MD. ABDUL GHANI

MBBS (CU), D.Card (BSMMU)

Ex-**ASSOCIATE PROFESSOR**

Department of Cardiology

North East Medical College & Hospital Sylhet.

BMDC Reg. No. A 18060



HEART SPECIALIST

Trained in INTERNAL MEDICINE

Trained in ADULT CARDIOLOGY

Trained in PEDIATRIC CARDIOLOGY

(Kerala, Hyderabad, India)

Ex. Senior Registrar and Cardiologist

Apollo Hospitals, Dhaka

Md. Billal Hussain Rony, 23 Y



Visit No : 3

Date : 25-12-2021

History:

abdominal pain = 2 days.

LOC / fit without convulsion = today =

hospitalized = DORB.

anorexia.

O/E:

Pulse: -80/min,

Erect:100/80 mm Hg;

S1 S2 M0

Clear lungs.

carotid bruit NONE.

Rx

1. Tab. Cefotil 500 mg (Cefuroxime Axetil)

১ + ০ + ১ - ৭ দিন। ✕

2. Tab. Algin 50 mg (Tiemonium methylsulphate)

১ + ১ + ১ - ১০ - দিন। ✕

3. Cap. Dexlan 30 mg (Dexlansoprazole)

১ + ০ + ১ (আহ্বের আগে) - ১ মাস।

4. Tab. Omidon 10 mg (Domperidone)

১ + ১ + ১ - যাওয়ার আধা ঘণ্টা আগে - ১ মাস।

Diagnosis:

FD.

Dyspepsia.

no h/o epilepsy nor nose bleed since

last visit 3 months back.

S. Fraxit

৩+০+৩ — ২ সপ্ত



২ মাস পরে আসবেন।

[Handwritten Signature]
25.12.21

Tests Advised:

1. USG of whole abdomen = (N)

2. Stool R/M/E (N)

3. Urine R/M/E (N)

চেম্বার : সিলেট মা ও শিশু হাসপাতাল

উপকর্ষ আ/এ, সোবহানীঘাট, সিলেট।

সাক্ষাতের সময়: বিকাল ৩টা থেকে সন্ধ্যা ৬টা পর্যন্ত।

সিরিয়ালের জন্য : ০১৭৩০-৮৫৮৮৩৩, (তরুবার বন্ধ)।



● Sobhanighat, Sylhet

● Tel : 0821-727933-41

● Hotline : 09636-300300

● E-mail : info@ibnsinahospitalsylhet.com.bd

● Web : www.ibnsinahospitalsylhet.com.bd

IBN SINA HOSPITAL SYLHET LTD.

STOOL EXAMINATION REPORT



ID No. : **Q250878**

Received : 26/12/2021 3:47PM

Print Date : 26/12/2021 5:07PM

Name : MR BILLAL HUSSAIN RONY

Sex: Male

Age: 23 y

Refd. by : ASSOC.PROF.DR. MD.ABDUL GHANI MBBS D-CARD.PGT.

PHYSICAL EXAMINATION

	Test Result
Appearance	Soft
Colour	Brown
Mucus	Nil
Blood	Nil


CHEMICAL EXAMINATION

	Test Result
Reaction	Acidic
Occult Blood test (O.B.T.)	Not done
Reducing substance	Not done

MICROSCOPIC EXAMINATION

	Test Result
Protozoa (Tropozoite)	Nil
Cysts of	Nil
Larva of	Nil
Ova of A.L.	Nil
Ova of A.D.	Nil
Ova of T.T.	Nil
Epithelial cells	Nil
Pus cells	Nil
RBCs	Nil
Macrophages	Nil
Fatty acid crystal	Nil
Fat Globules	Nil
Vegetable cells	(+)
Starch granules	(+)
Muscle fibres	Nil
Yeasts	Nil
Others	Nil


Md. Abdullah Al Limon
Medical Technologist (Laboratory)
Ibn Sina Hospital Sylhet Ltd.


Prof. Dr. Md. Amjad Hossain Khan
MBBS, M.Phil (Path)
Consultant Pathology
Ibn Sina Hospital Sylhet Ltd.



● Sobhanighat, Sylhet
● Tel : 0821-727933-42
● Mobile : 01713301523, 01972832741
● Email : info@ibnsinahospitalssylhet.com
● Web :ibnsinahospitalssylhet.com

IBN SINA HOSPITAL SYLHET LTD.

ULTRASONOGRAM REPORT

ID. No.	: Q250878	Receive: Dec 26, 2021 03:27 PM	Print: Dec 26, 2021 03:47 PM
Patient's Name	: MR BILLAL HUSSAIN RONY		
Age	: 23 year(s)	Sex	: Male
Refd. by	: ASSOC.PROF.DR. MD.ABDUL GHANI MBBS.D-CARD.PGT.		

Thank you for the courtesy of this kind referral

USG OF WHOLE ABDOMEN

- The Liver:** Normal in size measuring about 14.6 cm with homogeneous echotexture. No focal lesion is seen.
- Biliary Channels:** Intrahepatic biliary channels are not dilated. CBD: Not dilated.
- The gall bladder:** Normal in size. Wall thickness is normal. No echogenic structures, sludge or deposit is seen in GB lumen.
- The pancreas:** Appears normal.
- The spleen:** Normal in size and uniform in echopattern.
- Right kidney:** Normal in size shape and position; measuring about 9.7 cm x 3.5 cm. Cortical echogenicity is normal. Cortico-medullary differentiation is well. Pelvicalyceal systems are not dilated.
- Left kidney:** Normal in size shape and position; measuring about 9.2 cm x 3.5. Cortical echogenicity is normal. Cortico-medullary differentiation is well. Pelvicalyceal systems are not dilated.
- The urinary bladder:** Well filled and regular in outline. No intravesical lesion is seen.
- Prostate:** Normal in size measuring about (3.1 x 3.1 x 2.2) cm with uniform echopattern. Prostatic volume is about 11.8 cm³.
- Impression:** Normal sonographic study.

26-Dec-21

Dr. Rawshan Jahan

MBBS, MPH, DMU, TVS
Specialist (Training from Dhaka, New Delhi-India)
Consultant Sonologist
Ibn Sina Hospital Sylhet Ltd.

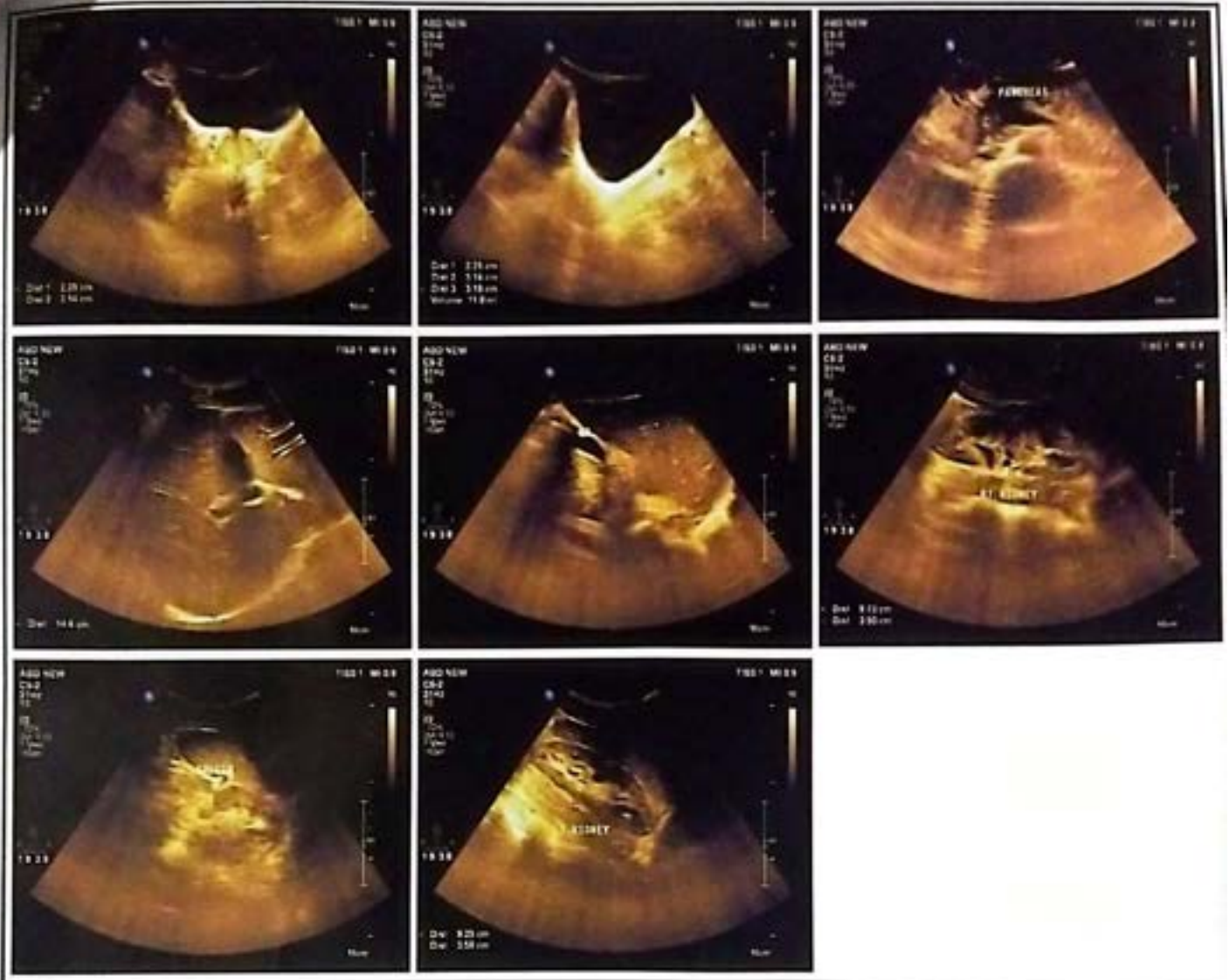IBN SINA HOSPITAL SYLHET LTD.

Sobhanighat Point, Sylhet

E-mail: ibnsinahospitalsylhetltd@gmail.com

Mobail: 01713301523, 01972832741

images





IBN SINA
Pioneer in Health Care



2650402

3

ROUTINE URINE EXAMINATION



● Sobhanighat, Sylhet
● Tel : 0821-727933-41
● Hotline : 09636-300300
● E-mail : info@ibnsinahospitalsylhet.com.bd
● Web : www.ibnsinahospitalsylhet.com.bd

IBN SINA HOSPITAL SYLHET LTD.

ID No. : **Q250878**

Received : 26/12/2021 3:47PM
Print Date : 26/12/2021 5:06PM

Name : MR BILLAL HUSSAIN RONY

Sex: Male

Age: 23 y

Refd. by : ASSOC.PROF.DR. MD.ABDUL GHANI MBBS.D-CARD.PGT.

Relevant estimations were carried out by Automated Urine Analyzer(LabUMat 2 + Urised 3, Hungary)& checked manually

PHYSICAL EXAMINATION	Test Result	Reference value
Colour	Straw	Straw/Yellow
Appearance	Clear	Clear
Specific gravity	1.004	1.016-1.022

CHEMICAL EXAMINATION	Test Result	Reference value
PH	7	4.5-8.0
Protein	Nil	Nil
Glucose	Nil	Nil
Ketone Body	Nil	Nil
Bilirubin	Absent	0.02 mg/dL
Urobilinogen	Normal	0.1-1.8 mg/dL
Nitrite	Absent	Absent

MICROSCOPIC EXAMINATION	Test Result	Reference value
Epithelial cells	0-2/HPF	1-5/HPF
Pus cells/WBC	0-2/HPF	0-5/HPF
RBC	Nil	Nil
Hyaline Cast	Nil	Nil
Granular Cast	Nil	Nil
WBC Cast	Nil	Nil
RBC Cast	Nil	Nil
Calcium-Oxalate	Nil	Nil
Uric Acid	Nil	Nil
Triple phosphate	Nil	Nil
Sulphonamide	Nil	Nil
Amorphous phosphate	Nil	Nil
Urates	Nil	Nil
Yeast/Candida	Nil	Nil
Spermatozoa	Nil	Nil
Trichomonas/Vaginalis	Nil	Nil
Others	Nil	Nil

Ref. Clinical diagnosis and managements by laboratory methods (John Bernard Henry)

Md. Abdullah Al Limon
Medical Technologist (Laboratory)
Ibn Sina Hospital Sylhet Ltd.

Prof. Dr. Md. Amjad Hossain Khan
MBBS, M.Phil (Path)
Consultant Pathology
Ibn Sina Hospital Sylhet Ltd.



পপুলার মেডিকেল সেন্টার এন্ড হসপিটাল সিলেট POPULAR MEDICAL CENTRE & HOSPITAL SYLHET

সোহানীয়াট, সিলেট। ফোন : ০৯৬৬৬৭৭২২১১, E-mail: popularsylhet2005@gmail.com, www.popularsylhet.com
কাজলশাহ ঢাকা পপুলার (পপুলার মেডিকেল সেন্টার লিমি) এর একটি সহযোগী প্রতিষ্ঠান



USG REPORT



Invoice No :	A2107001335	Invoice Date :	28/07/2021	Delivery Date :	28/07/2021	Report No. :	22107034953
Patient Name :	MR. BILLAL HUSSAIN	Age :	23Y	Gender :	M		
Ref. Doctor :	Asstt. Prof. Md. Abdul Ghanl, MBBS, D.Card, PGT						
Test Name :	Ultrasonogram of Whole Abdomen						

Summary of findings

Liver:	Normal in size. Parenchyma is homogeneous. No focal lesion is seen.
Gall Bladder:	Well-outlined. Wall thickness is normal. Lumen is clear.
Biliary Channels:	Biliary tree is not dilated.
Pancreas:	Normal in size with echotexture. MPD is not dilated.
Spleen:	Normal in size and echotexture.
Right Kidney:	Normal in size, shape and position. Bipolar length of right kidney is 10.7 cm . Cortical echogenicity is normal. Cortico medullary differentiation is maintained. Pelvicalyceal system is not dilated. There is no evidence of any calculus or any sign of ureteric obstruction.
Left kidney:	Normal in size, shape and position. Bipolar length of left kidney is 10.9 cm . Cortical echogenicity is normal. Cortico medullary differentiation is maintained. Pelvicalyceal system is not dilated. There is no evidence of any calculus or any sign of ureteric obstruction.
Urinary Bladder:	Well filled and regular in outline. No intravesical lesion is seen.
Prostate:	Normal in size (measuring about 3.2 cm x 2.0 cm x 2.7 cm). Echotexture is homogeneous. Prostatic volume is about 9.5 cm ³ .



HN:

Powered By: MYSOFT Ltd.

Comment: Normal study at ultrasound.

Prepared By ::
Ruhel Ahmed

Nirupoma Das
28.07.21.

DR. NIRUPOMA DAS
MBBS, DMUD, PGT (SWMCH)
Special Trained on TVS, Fetal Anomaly
Scan & Duplex Color Doppler Study
Consultant Sonologist
Popular Medical Centre & Hospital, Sylhet



ECHOCARDIOGRAPHY

(Echo- Screening)

ID No	: P-065774	Date	: 27.07.2021
Name	: Md. Billal Hussain Rony	Age	: 23y
Investigation	: Echo-Screening	Sex	: Male
Refd. By	: Assoc. Prof. Dr. Md. Abdul Ghanl MBBS, D. Card		

Measurement:

LA	=32	mm	IVSd	=08	mm	LVEF	=62	%
AO	=27	mm	PWd	=07	mm			
ACS	=19	mm	LVIDd	=47	mm			
			LVIDs	=31	mm			

Description:

LA : Normal.
 LV : Normal. No RWMA. Good LV systolic function EF~62%.
 RA : Normal.
 RV : Normal.
 MV : Normal.
 AV : Normal.
 PV : Normal.
 TV : Trivial TR.
 IAS : Intact.
 IVS : Intact.

No PE, thrombus or vegetation seen.

Impression:

- Good LV systolic function (EF~62%).
- No regional wall motion abnormality.
- Good RV systolic and diastolic function.
- No pulmonary hypertension.
- Trivial TR.

** Color flow mapping & Doppler study are also done.

Dr. Md. Abdul Ghanl
 MBBS (D), D. Card (D)
 Associate Professor
 North East Medical College Hospital
 Trained in Pediatric Echocardiography
 in India (Hyderabad & Kerala)

SM 16FT No. 1

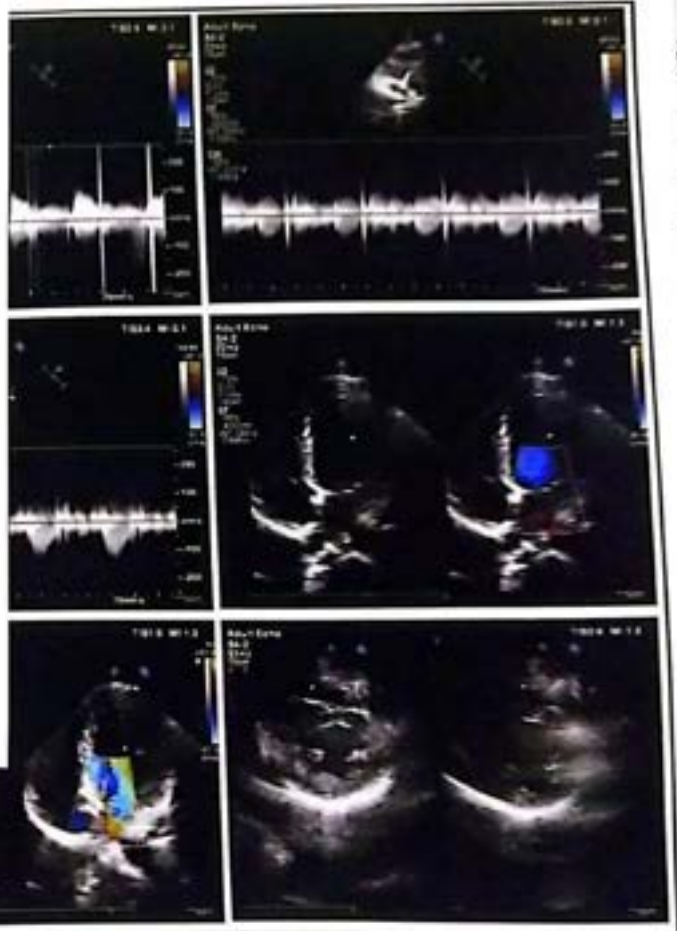
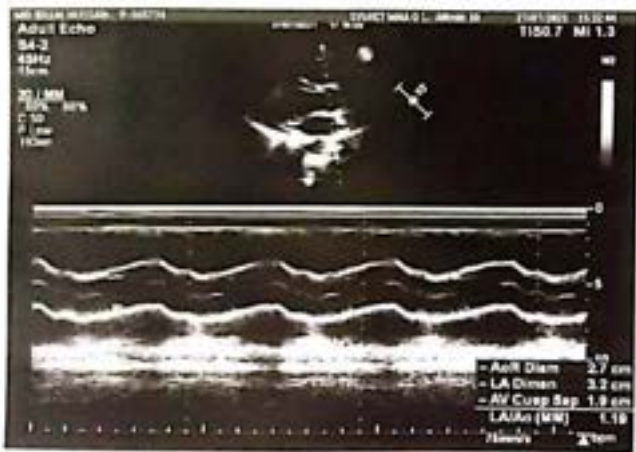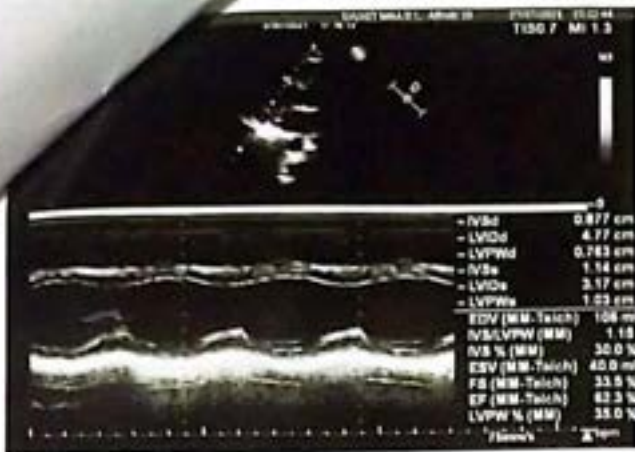
HOSPITAL
Net
835
noshbd.com



Innovation + you

Study Date: 27/07/2021

ynet.
9307
8835
com
com



83
y/d

Signature

Signature:

Name(Print):

Date:




HAEMATOLOGY - REPORT

Invoice No: 48884	Patient ID : 65849	Mobile : 01624549583
Patient Name : Md.Billal Hussain Rony	Age : Y 23 M 0 D 0	Sex : Male
Referred By : Prof. Dr. Md. Abdul Ghani	Ward/Cabin :	Speciman : Blood
Receipt Date : 28-Jul-2021 03:09 PM	Delivery Date :28-Jul-2021 05:00 PM	

Test Name	Result	Reference Value
Hb%	14.2 g/dl	Male: 12-17, Female: 11.5-15.5 g/dl
ESR : Westergreen Method	24 mm/1st Hour	Male: 0-10, Female: 0-20 mm/1st Hour
Differential Count		
Neutrophils	71 %	(40-75)%
Lymphocytes	26 %	(20-40)%
Monocytes	02 %	(2-10)%
Eosinophils	01 %	(1-6)%
Basophils	00 %	(0-1)%
Others		
P.C.V/HCT	45 %	Male: 40-52%, Female: 36-48%
M.C.V	79 fL	80-95fL
M.C.H	25 pg	27-34pg
M.C.H.C	31 g/dl	30-35g/dl
M.P.V	7.9 fL	7.20-9.20fL
Total Count		
Red Blood Cells	5.64 x10 ⁶ /μl	Male: 4.5-5.5x10 ⁶ /μl, Female: 3.8-4.8x10 ⁶ /μl
White Blood Cells	8.9 x10 ³ /μl	4.0-11.0x10 ³ /μl
Platelets Count	290 x10 ³ /μl	150-450x10 ³ /μl


Checked By :
 Medical Technologist(Lab)
 Sylhet Maa O Shishu Hospital


Dr. Md. Sabbir Hossain
 MBBS, M. Phil (Path) Trained in BSMMU & UK
 Associate Professor of Pathology
 Sylhet Maa O Shishu Hospital

DR. MD. ABDUL GHANI

MBBS (CU), D.Card (BSMMU)

ASSOCIATE PROFESSOR

Department of Cardiology

North East Medical College & Hospital Sylhet.

BMDC Reg. No. A 18060

**HEART SPECIALIST**

Trained in INTERNAL MEDICINE

Trained in ADULT CARDIOLOGY

Trained in PEDIATRIC CARDIOLOGY

(Karala, Hyderabad, India)

Ex. Senior Registrar and Cardiologist

Apollo Hospitals, Dhaka

Md. Billal Hussain Rony, 23 Y



2107267473

Visit No : 2

Date : 11/09/2021

History:Nose bleed - two events - 2 days back.
sore mouth.

FEVER / COUGH/ RASH = none.

O/E:

Pulse: ~80/min,

Erect:100/85 mm Hg;

S1 S2 M0

Clear lungs.

carotid bruit NONE.

HIT on the right.

Diagnosis:

AN.

Dyspepsia.

?? Epilepsy : Adv: Neuro consultation.

HIT - right - Adv: ENT consultation.

Rx

1. Tab. Cefotil plus (500+125) mg (Cefuroxime Axetil + Clavulanic Acid)
1 + 0 + 1 - ৭ দিন।
2. Tab. Fenadin 120 mg (Fexofenadine Hydrochloride)
0 + 0 + 1 - ১০ দিন।
3. Drop. Afrin 0.025% (Oxymetazoline HCl)
২ + ০ + ২ (ফোঁটা) ২ নাকে - ১ সপ্তাহ
4. Cap. Supravit M (Multivitamin & Multimineral)
1 + 0 + 1 - ১ মাস।
5. Tab. Riboson 5 mg (Riboflavin)
1 + 1 + 1 - ১০ দিন।
6. Tab. Erata 250 mg (Levetiracetam)
1 + 0 + 1 - চলবে - until consultation with Neurologist.

Tests Advised:

1. CBC
2. Bleeding time (BT), Clotting time (CT)

Referred To Neurologist for h/o ?epilepsy.

ENT specialist for nose bleed.

Traxyl 500
1+1+1 = বেশী রক্তক্ষরণ হলে।

Abdul Ghani
11.9.21

ডেয়ার : সিলেট মা ও শিশু হাসপাতাল

উপকর্ষ আ/এ, সোবহানীঘাট, সিলেট।

সাক্ষাতের সময়: বিকাল ৩টা থেকে সন্ধ্যা ৬টা পর্যন্ত।

সিরিয়ালের জন্য : ০১৭৩০-৮৫৮৮৩৩, (শুক্রবার বন্ধ)।



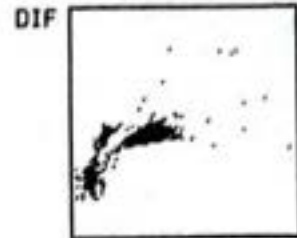
SYLHET MA O SHISHU HOSPITAL

Name :	Patient ID :
Comments :	Sample ID : 62192
	Type : STANDARD

Operator ID :

Date : 11/09/2021 06:28:59PM Seq : 00011

	Result	Flags	Unit
WBC	7.4	s	10 ³ /μL
NEU%	73.7	*	%
LYM%	25.5	*	%
MON%	0.0	*L	%
EOS%	0.7	*L	%
BAS%	0.1	*	%
NEU	5.5	*	10 ³ /μL
LYM	1.9	*	10 ³ /μL
MON	0.0	*L	10 ³ /μL
EOS	0.1	*	10 ³ /μL
BAS	0.0	*	10 ³ /μL
RBC	5.75		10 ⁶ /μL
HGB	14.3		g/dL
HCT	44.6		%
MCV	77.5		fL
MCH	24.9	l	pg
MCHC	32.1		g/dL
RDW	14.9		%
PLT	307		10 ³ /μL
MPV	7.7		fL



This is Machine Generated Report
 Final and Consultant Signed report
 Will be Provide as soon as Possible

AA


**SHISHU
HOSPITAL**

License No. HSM4313111

Upokanta R/A, Subhanighat, Sylhet.

Phone: 0821-719306, 719307

Mobile : 01730-858833, 01730-858835

E-mail : info@smoshbd.com

Web : www.smoshbd.com

SEROLOGY - REPORT

Invoice No: 52192	Patient ID : 68878	Mobile : 01624549783
Patient Name : Md Billal Hussain Rony	Age : Y 23 M 0 D 0	Sex : Male
Referred By : Prof. Dr. Md. Abdul Ghani	Ward/Cabin :	Specimen : Serum
Receipt Date : 11-Sep-2021 04:24 PM	Delivery Date : 11-Sep-2021 05:00 PM	
Test Name	Result	Reference Value
Bleeding Time (BT)	2 Min 30 Sec ✓	1-7min
Clotting Time (CT)	04 Min 20 Sec ✓	5-10min

 SYLHET
MAA

 SHISHU
HOSPITAL


 Checked By :
 Medical Technologist(Lab)
 Sylhet Maa O Shishu Hospital

Dr. Md. Zakir Hossain
 MBBS, DCP (Clinical Pathology) M.Phil
 (Microbiology)
 Consultant Pathologist & Microbiologist
 Sylhet Maa O Shishu Hospital