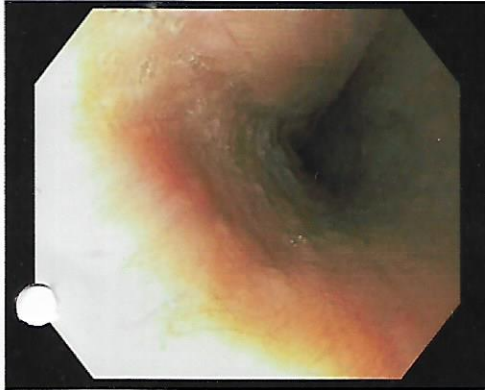
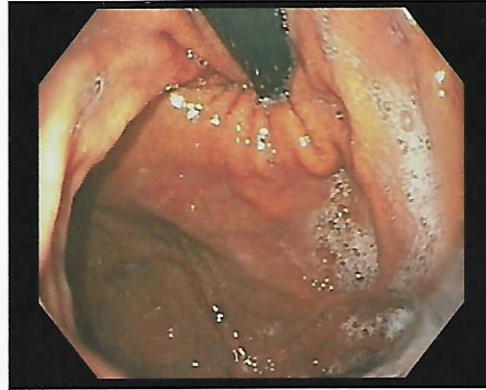

Identity No.	145801	Visit Date	02 June, 2023
Patient Name	Noyon	Age / Sex	38 / Male
History	N/A	Instrument	N/A
Referrer	Professor Dr. Md. Makhsudul Alam, MD(Gastro)	Bed	OPD

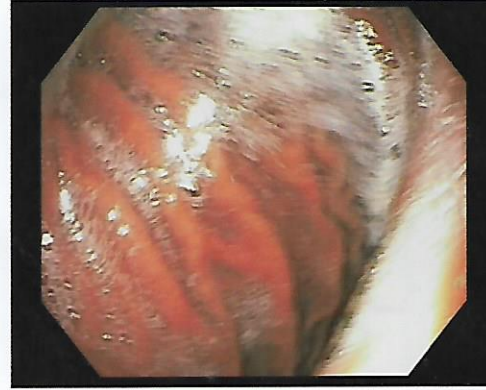ENDOSCOPIC PROCEDURE REPORT



Oesophagus



Fundus



Body

Procedure : ENDOSCOPY

Indication : N/A

Medication : Nil

Room No 303 Popular, Bogura

OESOPHAGO - GASTRO - DUODENOSCOPIC FINDINGS

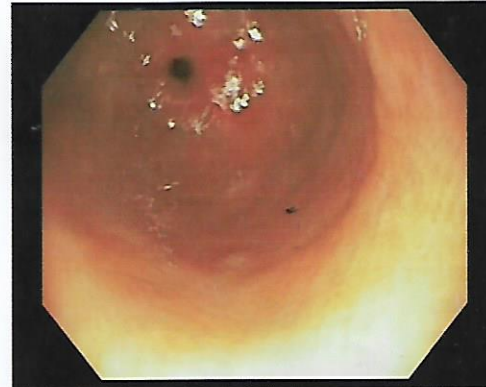Oesophagus : Normal.

Stomach : Shows diffuse erythema in the fundus, body & antrum.

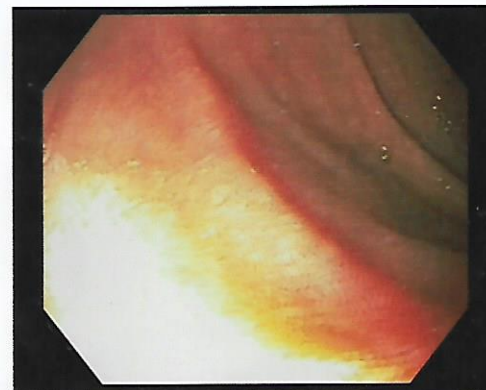
Duodenum : Normal up to the second part.

Biopsy : Not taken.

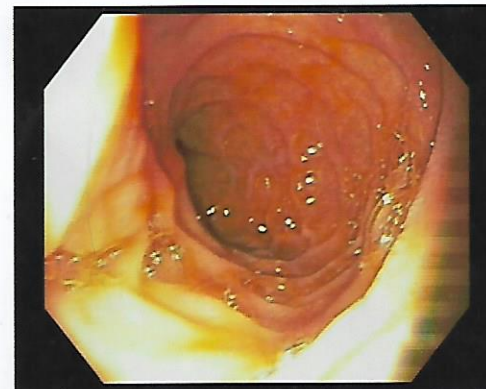
Endoscopic Diagnosis : Mild pangastritis.



Antrum



1st part of duodenum



2nd part of duodenum



Professor Dr. Md. Makhsudul Alam

Fellowship in LIVER Disease, QEHB Birmingham, UK
MBBS, MD (Gastroenterology)