




## PERSONAL DATA AND EMERGENCY CONTACT

**Name:** JUBAIRUL HAQ  
**Father's Name:** MD ABDUR RAB  
**Mother's Name:** JIBUN NAHER  
**Spouse's Name:** MEHERIN NAHAR  
**Permanent Address:** FLAT# A10, RAJIA TOWER, KALLANPUR, MIRPUR ROAD,  
DARUS SALAM, KALYANPUR - 1207, DHAKA  
**Emergency Contact:**  
**Name:** SYED TARIQUL ISLAM  
**Relationship:** FRIEND  
**Address:** FLAT#A10, RAJIA TOWER, KALLANPUR, MIRPUR ROAD,  
DARUS SALAM, KALYANPUR - 1207, DHAKA  
**Telephone No.:** +8801711358823








## PERSONAL DATA AND EMERGENCY CONTACT

**Name:** MEHERIN NAHAR  
**Father's Name:** ENAMUL HAQUE  
**Mother's Name:** NAZMUN NAHAR NASRIN  
**Spouse's Name:** JUBAIRUL HAQ  
**Permanent Address:** HOUSE#6/A/1, FLAT-A-10, RAJIA TOWER, KALLAYANPUR  
MAIN ROAD, MIRPUR, MIRPUR - 1216, DHAKA

**Emergency Contact:**  
**Name:** JUBAIRUL HAQ  
**Relationship:** SPOUSE  
**Address:** HOUSE#6/A/1, FLAT-A-10, RAJIA TOWER, KALLAYANPUR  
MAIN ROAD, MIRPUR, MIRPUR - 1216, DHAKA  
**Telephone No.:** +8801709697569



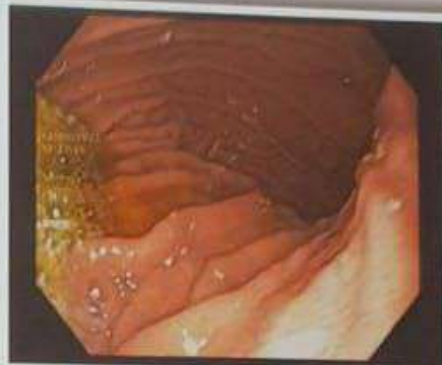
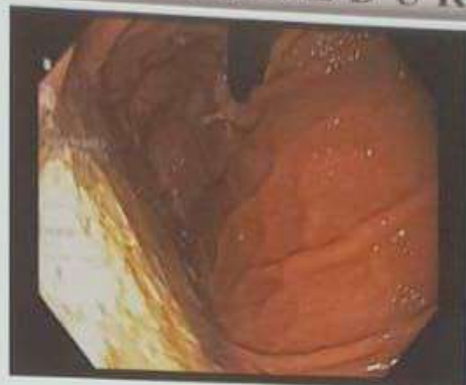
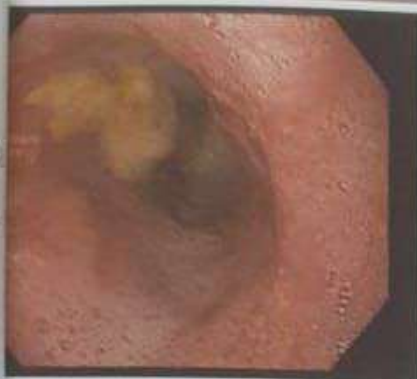# CRESCENT GASTRO LIVER & GENERAL HOSPITAL LTD.

25 / I, Green Road, Dhanmondi, Dhaka.  
Tel 9671571, 58615134. Mobile : 01926100100

Identity No.	00003273	Visit Date	12 March, 2023
Patient Name	Mrs. Meherin Nahar	Age / Sex	30 / Female
Referral	Dr. Mohammed Asadur Rahman	Instrument	OLYMPUS CV-170
		Bed	OPD

## ENDOSCOPIC PROCEDURE REPORT



Procedure : UPPER G. I. TRACT ENDOSCOPY

Indication : N/A

Anesthesia : TIVA with Inj. Propofol

Surgeon : Dr. Alamgir Haider. MBBS, DA.

### FINDINGS :

#### Esophagus:-

Retains food and fluids. After suction and propulsion forward, esophagus is seen hugely dilated and aperistaltic. G-E junction is tight and does not open from air insufflation. Scope passed through, with little pressure.

#### Stomach:-

Mucosa of the cardia, fundus, body and antrum appear normal.

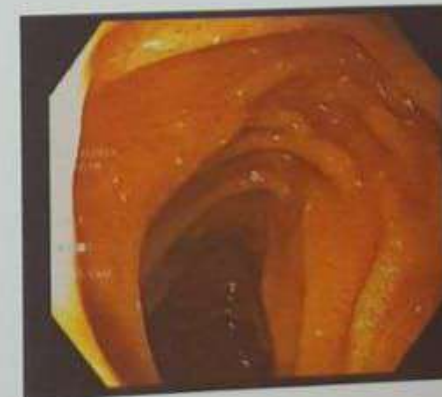
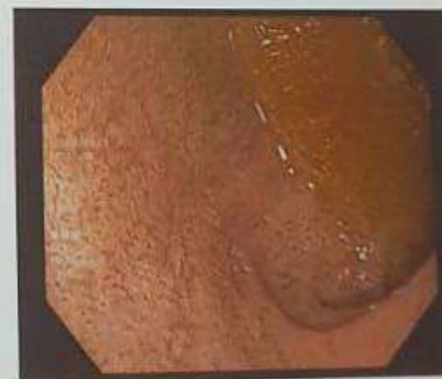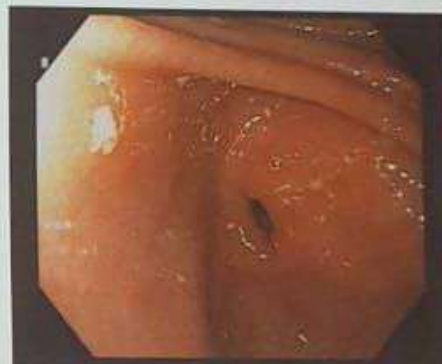#### Duodenum:-

First bulb, post-bulbar area and second part appear normal.

Biopsy:- Not taken.

### COMMENTS :

Esophageal achalasia of the esophagus.



12.03.2023

Mohammed Asadur Rahman

BS, MD (Gastroenterology)

Department of Gastroenterology

Agabandhu Sheikh Mujib Medical University

Address: T. H. RIYAD | www.bissoft.net

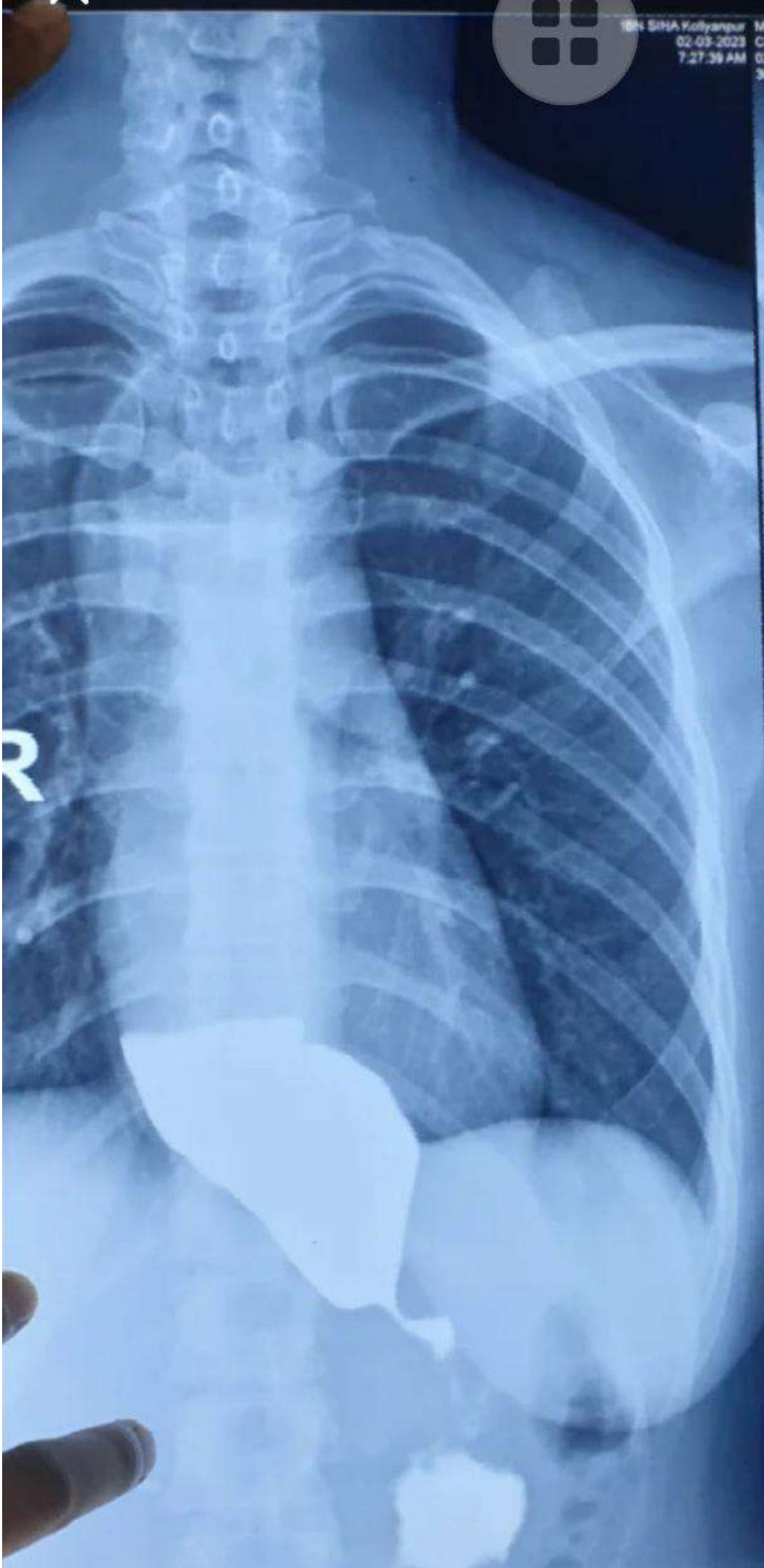
Distributed by: AL-FATAH INTERNATIONAL

Phone: +880-2-9676101

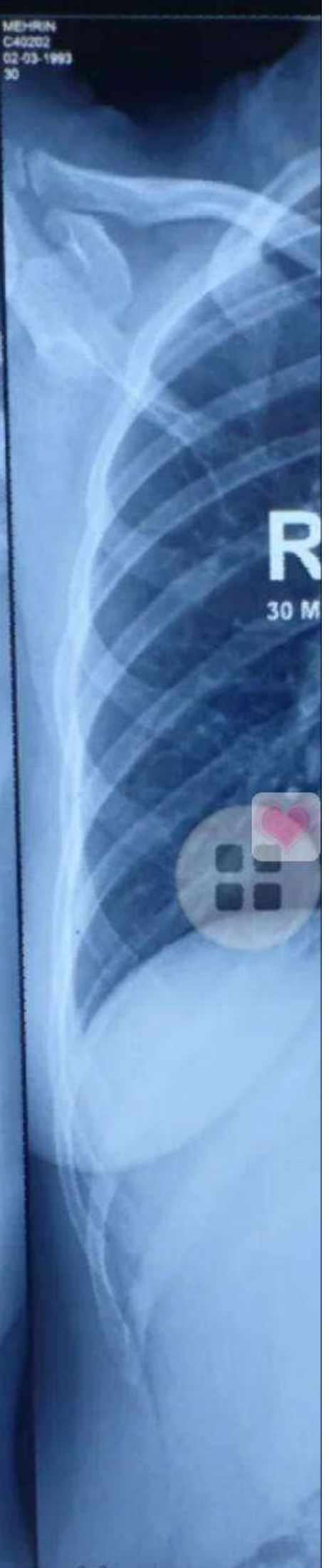
Fax: +880-2-9676881

Email: info@alfatah-bd.com

IBN SINA Kalyanpur MEHRUN  
02-03-2023 C40202  
7:27:39 AM 02-03-1993  
30



R



R  
30 M







- 1/1-B, Kallyanpur, Mirpur, Dhaka-1216
- Serial : 01703 725590, 01311 799593-4
- Phone : 8091332-6, 8035905, 8091773
- E-mail : ismchoffice@gmail.com
- Web : www.ibnsinatrust.com
- Hotline : 09610009616

## IBN SINA MEDICAL COLLEGE HOSPITAL


ISO 9001:2015 Certified

ID. No	: C40202	Received date	: 2 Mar 2023	Printed date	: 2 Mar 2023 03:00PM
Patient Name	: MEHRIN	Age	: 30 y(s)	Sex	: Female
Exam	: XR BA-SWALLOW DIGITAL	Ref. By	: Assoc. Prof.Dr.Md Mostafizur Rahman MBBS,MS(Surgery)		

### Ba-Swallow of Esophagus

Barium has opacified the esophagus & enters in to the stomach.  
There is smooth tapering of lower esophagus to the level of gastro-esophageal junction giving rat tail appearance with proximal dilatation and hold up of contrast.  
Mucosal pattern appears normal.

**Comment : Features consistent with achalasia.**

  
**Dr. Kazi Zahurul Haque**  
MBBS,MD (Radiology & imaging),  
BSMMU (EX-PG Hospital)  
Consultant  
Shaheed Suhrawardy Medical College  
& Hospital, Dhaka.

*Prepared by- Shojib Ahmad*  
3/3/2023 8:34:23 PM



### Discharge Summary

UHID	: 7905	IP. No.	: 23/512
Patient	: MEHRIN NAHAR	Age / Gender	: 30 Y- 0 M- 2 D/Female
Address	: H- RAZIA TOWER KOLLAN PUR DHAKA. DHAKA. BANGLADESH		
Bed Category	: DB	Bed No.	: 302
DOA	: 17/03/2023 11:11AM	DOD	: 19/03/2023 08:57AM
Consultant	: DR. MOHAMMAD ASADUR RAHMAN		
Refd By	:		

#### Diagnosis :

**ACHALASIA CARDIA WITH BA**

#### Brief Clinical History :

DIFFICULTY IN DIGLUTITION  
VOMITING

#### Medication Received During Hospital :

#### \*\*Investigation profile :

ALL ARE SUPPLIED WITH PATIENT.

#### \*\*Operation Note/ Procedure Note:

DATE: 18/3/23

N/P: BALLOON DILATATION 1ST SESSION

INDICATION: ACHALASIA CARDIA

CONSULTANT: DR. MOHAMMAD ASADUR RAHMAN

#### \*\*Treatment On Discharge

CAP. CEF 3 200 MG

1+0+1----10 DAYS

CAP. INPRO 20 MG

1+0+1----BEFORE MEAL ----15 DAYS

TAB. NAPA 500 MG

1+1+1----AFTER MEAL ----5 DAYS

TAB. EMISTAT 8 MG

1+1+1----5 DAYS IF VOMITING

TAB. BILFAST 20 MG

1+0+0----10 DAYS

TAB. MONAS 10 MG

0+0+1---CONTINUE

TAB. DOXIVA 200 MG

1+0+1----CONTINUE


AROFLO INHALER 250

2 PUFFS ----12 HOURLY ---CONTINUE

#### \*\*Advice On Discharge :

FOLLOW UP AFTER 1 MONTH

sup. Ulfate 2TSF x 8 hourly (30min before  
→ 20 days.

Prepared By : 

Checked & Signed By : 