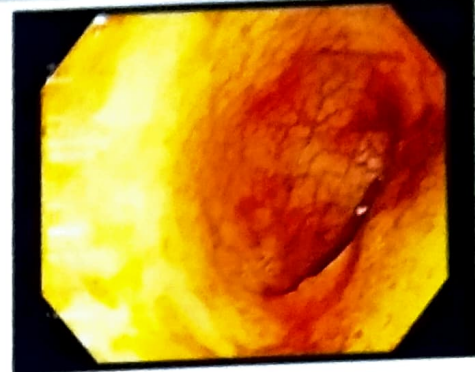
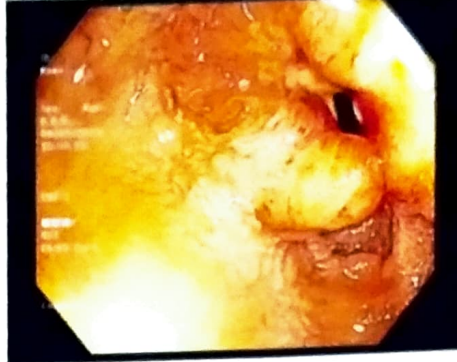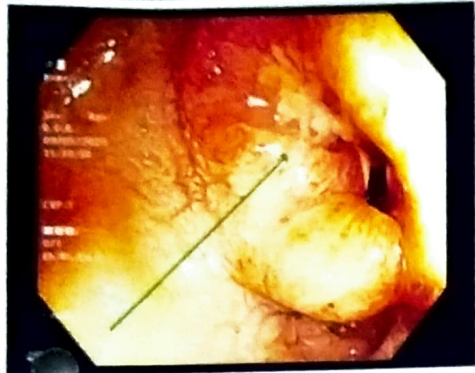




Identity No. 108345
Patient Name Mr. Shazahan Ali
History N/A
Referrer Prof. Dr. Md. Mahfuzar Rahman MBBS, MD FACP

Visit Date 09 May 2023
Age / Sex 56 / Male
Instrument N/A
CP OPD

ENDOSCOPIC PROCEDURE REPORT



Procedure : FULL COLONOSCOPY

Indication : SAIO

Medication : K-Y Jelly.Inj. Hypnofast 2 mg

FINDINGS :

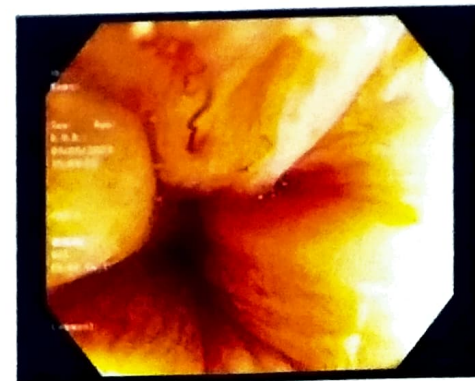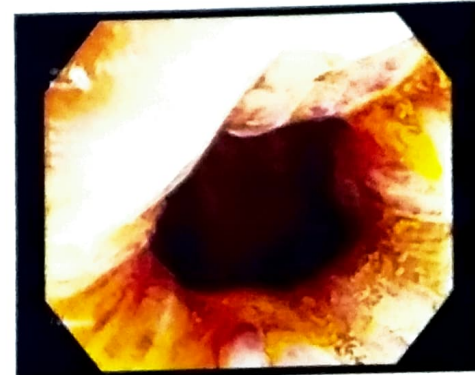
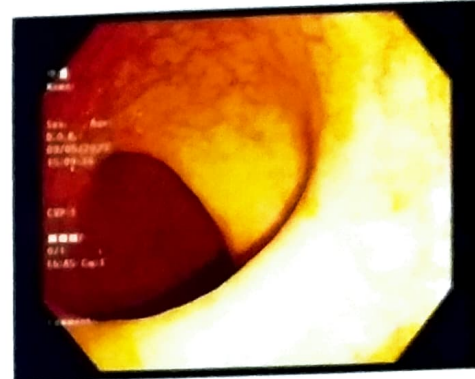
• **Seen Up To 30 cm from the anal verge:-**

A circumferential friable growth was noted in colon at about 30 cm from the anal verge with narrowing of the lumen; scope could not be passed beyond. Columns of haemorrhoid were seen in anal canal.

• **Biopsy:-** Taken.

COMMENTS : * Suggestive of malignant growth in sigmoid colon with narrowed lumen at about 30 cm from the anal verge.

*Haemorrhoids.



PROF. DR. JIMMA HOSSAIN

MBBS, MD (Gastroenterology)
 Trained in Advanced Endoscopy, Chennai, India.
 Prof. of Gastroenterology, Rangpur Medical College