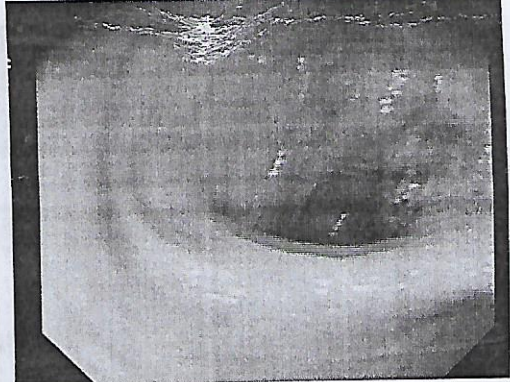
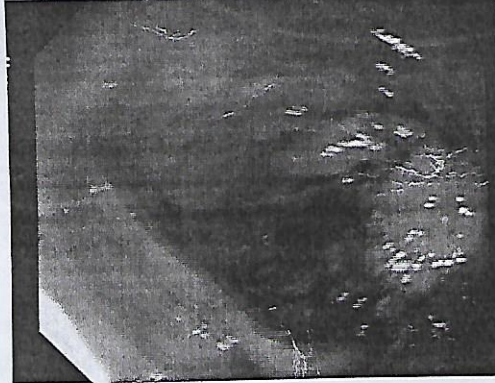
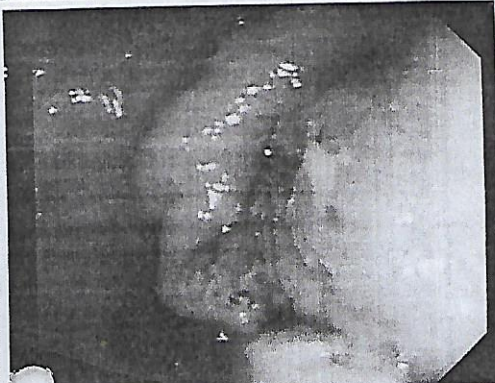

Identity No.	00005273	Visit Date	09 April, 2023
Patient Name	Kisher Shorma	Age / Sex	60 / Male
History	Abdominal pain	Instrument	N/A
Referrer	Prof.Dr.Bimal Chandra Roy,MBBS.FCPS(Surgery)	Bed	OPD

ENDOSCOPIC PROCEDURE REPORT



Procedure : COLONOSCOPY

Indication : SAIO

Medication : Inj Hypnofast, Lidocaine,

FINDINGS :

- **Seen Up To the 40 cm of colon:-**

An irregular ulceroproliferative growth is seen at the 40 cm from anal verge. The growth causes complete luminal narrowing, hence scope has not passed further. Rest of the mucosa, vascular pattern and the lumen of the colon appear normal although including anal canal.

- **Biopsy:-** Taken.

COMMENTS : Suggestive of Malignant Colonic Growth with luminal obstruction.

