

01766663099

LABAID LTD. (DIAGNOSTICS), RANGPUR

House 69, Road 1, Dhap Jail Road, Rangpur, Tel: 0521-56278, 56279, 56280, 56281, e-mail-info@labaidgroup.com, www.labaidgroup.com



Identity No.	2471	MRN	R525040	Visit Date	25/12/2022
Patient Name	MR. REZAUL KARIM	Bed		Age/Sex	34 / Male
Referrer	ASSO. PROF. DR. MD. NAUSHAD ALI ,MBBS, FCPS,			Instrument	N/A

PROCEDURE REPORT

Procedure : Upper G I TRACK Endoscopy

Indication : Dyspepsia

Medication : N/A

FINDINGS :

•Oesophagus:-

The mucosa, vascular pattern, lumen and peristalsis appeared normal.

•Stomach:- Normal.

•Duodenum:-

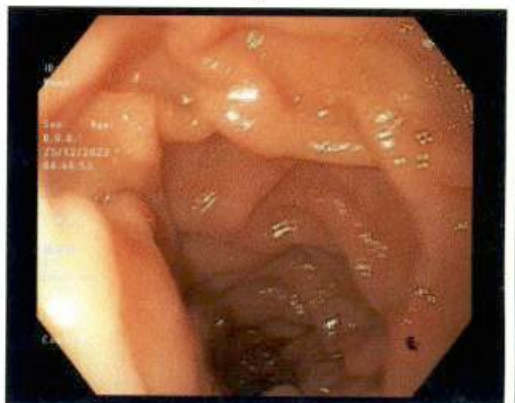
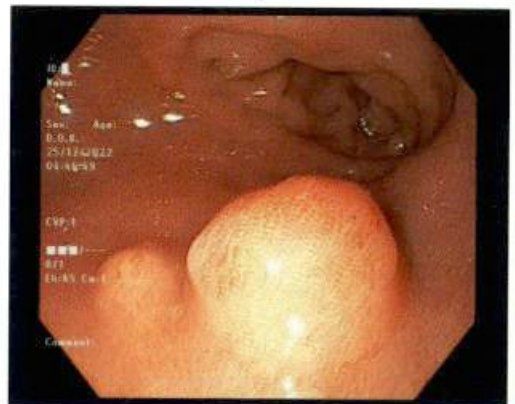
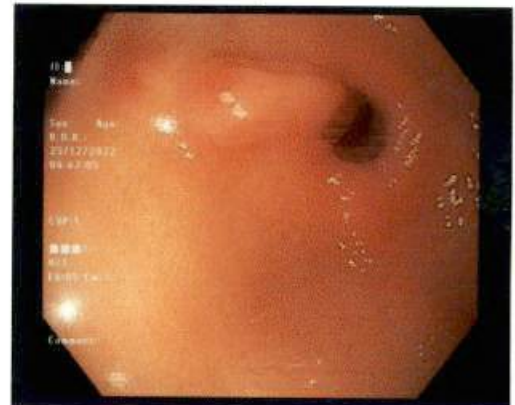
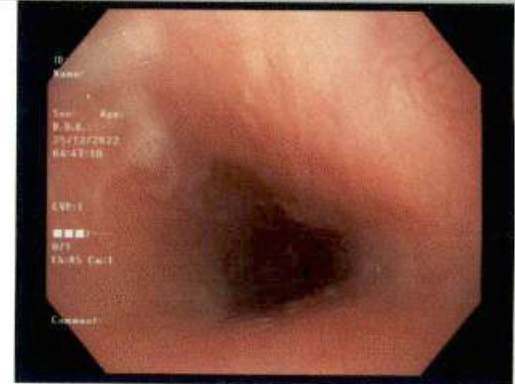
A pedunculated polyp seen in the bulb. second part appeared normal.

•Biopsy:- Not taken.

COMMENTS :

Duodenal polyp.

Adv. Endoscopic polypectomy.



DR. MD. NAUSHAD ALI

MBBS (DMC), FCPS(Medicine), MD(Gastroenterology)

Associate Professor of Gastroenterology

Rangpur Medical College & Hospital

01766663099

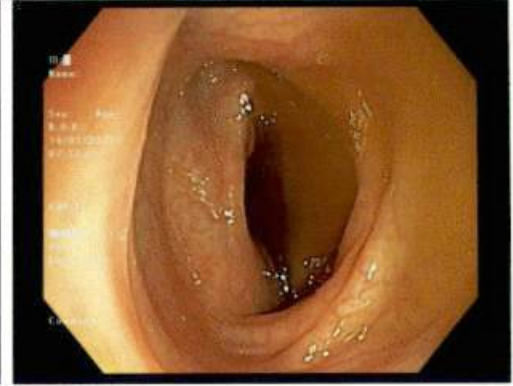
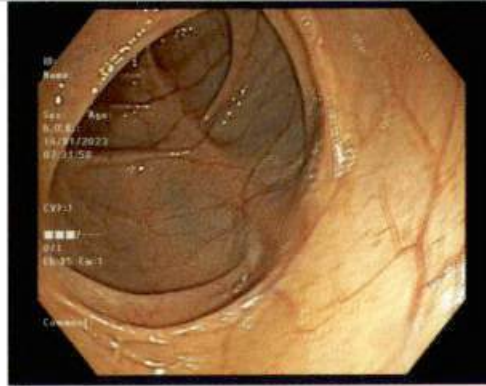
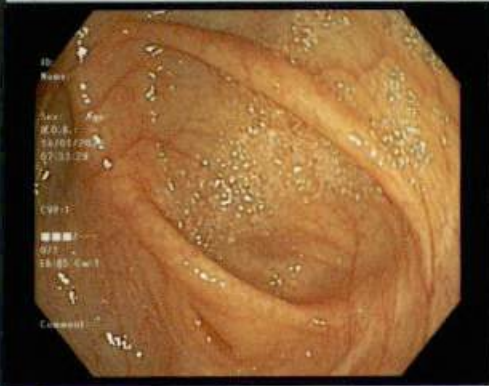LABAID LTD. (DIAGNOSTICS), RANGPUR

House 69, Road 1, Dhap Jail Road, Rangpur, Tel: 0521-56278, 56279, 56280, 56281, e-mail-info@labaidgroup.com, www.labaidgroup.com

LABAID
Diagnostics

Identity No.	2692	MRN	R529012	Visit Date	14/1/2023
Patient Name	MR. REZAUL KARIM	Bed		Age/Sex	34 / Male
Referrer	ASSO. PROF. DR. MD. NAUSHAD ALI ,MBBS, FCPS,			Instrument	N/A

COLONOSCOPIC PROCEDURE REPORT



Procedure : COLONOSCOPY

Indication : Altered bowel habit

Medication : INJ. Pethidine (40mg)

FINDINGS :

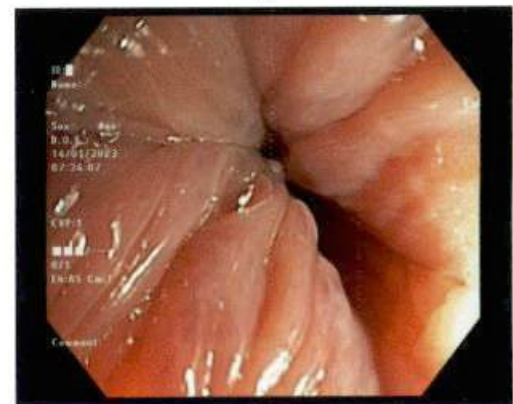
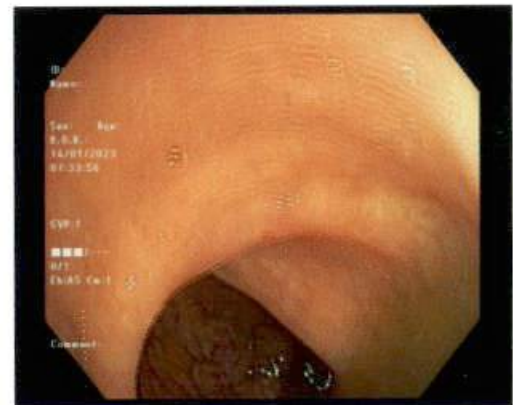
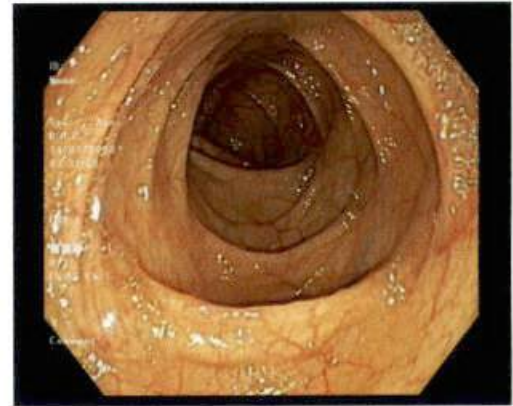
•Seen Up To Caecum:-

The mucosa, vascular pattern and the lumen of the whole colon including the rectum and anal canal appeared normal.

•Biopsy:- Not taken.

COMMENTS :

Normal colon, rectum and anal canal at Colonoscopy.



DR. MD. NAUSHAD ALI
 MBBS (DMC), FCPS (Medicine), MD (Gastro)
 Associate Professor of Gastroenterology
 Rangpur Medical College & Hospital