

Dr. Nusrat Zaman MBBS, FCPS

Senior Consultant

Obstetrics & Gynaecology

BMDC Reg. no: A 10707

Visit Date / Prescription No. : 29 Sep 2022 / OPD-202209291172706

Name: AKILA RAISA

UHID: 1000477943

Age: 24 Y 0 M 25 D

Gender: Female

Presenting Symptoms

Missed Period
11 weeks +

Past Medical / Surgical History

Married 2 yrs

Menstrual History

LMP-10/7/2022

M/C Delayed

Investigation History

Scan- 5/9- 5 weeks

27/9- 8 weeks

Empty Sac

Vital Signs

BP(mmHg) : 100/60

WT(Kg) : 59.00

Follow-up & Advice

Ad- To Attend Emergency

Medications

- | | |
|----------------------------|--|
| 1. TAB LEVOFLOXACIN 500 MG | Take 1 TAB Once daily for 7 Days
Oral 0+0+1 |
| 2. TAB TIEMONIUM 50 MG | Take 1 TAB Twice daily for 5 Days
Oral 1+0+1 |
| 3. TAB MISOPROSTOL 200 MCG | Take 1 TAB Thrice daily for 7 Days
Oral 1+1+1 |

OPD PRESCRIPTION

In case of experiencing any allergic reaction, skin rashes or any other reaction which you think may be due to medication,
Please contact immediately to Emergency department of United Hospital Ltd.
Emergency Contact No: 01914001234, Hotline: 10666 and For Appointment : 02 22 22 62 466

Prescribed By: Dr. Nusrat Zaman

Note : This is Computer Generated Prescription. *****

Call for Home Sample Collection: 01914 001 220

Print Date & Time : 29/09/2022 01.21 PM

0+ve

Dr. Nusrat Zaman MBBS, FCPS
Consultant, Obstetrics & Gynaecology
BMDC Reg. No. A-10707

AKILA RAISA .
(477943)

LMP - 10/7/2022

EDD -

Married - 2 yrs.

M/C Delayed M.C

P. qu/w

missed Periods

11+ weeks

Scan 5/9 - 5 wks.

+ 27/9 - 8 wks.

empty sac

M.T. LEVONORIN (5000) (3)

0+0+1 - 7 days

(37)

1 T. ALGIN (500) (10)

1+0+1 - 5 days

1 T. LEXOTANIL

0+0+1 -

1 T. CYTOMIS (200000)

1+1+1 - 7 days

cut

P To attend emergency

IBN SINA DIAGNOSTIC & CONSULTATION CENTER, BADDA

ISO 9001:2015 Certified

ULTRASONOGRAM REPORT

I.D. No : B471211 Received date : 6 Sep 2022 Printed date: 6 Sep 2022 10:59AM
Name of Pt. : MRS. AKILA RAISA Age : 25 y(s) Sex: Female
Referred by : DR FARHANA BINTY RASHID, MBBS,FCPS(GYNAE AND OBS),BCS
Part Scanned: USG LOWER ABDOMEN 4D

Thank you for your kind referral

Urinary bladder is well filled. Wall thickness is within normal limit.

No intravesicle lesion is seen.

Uterus is gravid containing single gestational sac with regular echogenic walls.

MSD is 16 mm corresponding gestational age is 05 weeks.


Foetal pole is yet not seen within the sac.

Both tubo-ovarian regions are normal.

No collection is seen in pouch of Douglas.

IMPRESSION: Early intrauterine pregnancy of about 05 weeks.

Follow up scan after 02 weeks suggested.

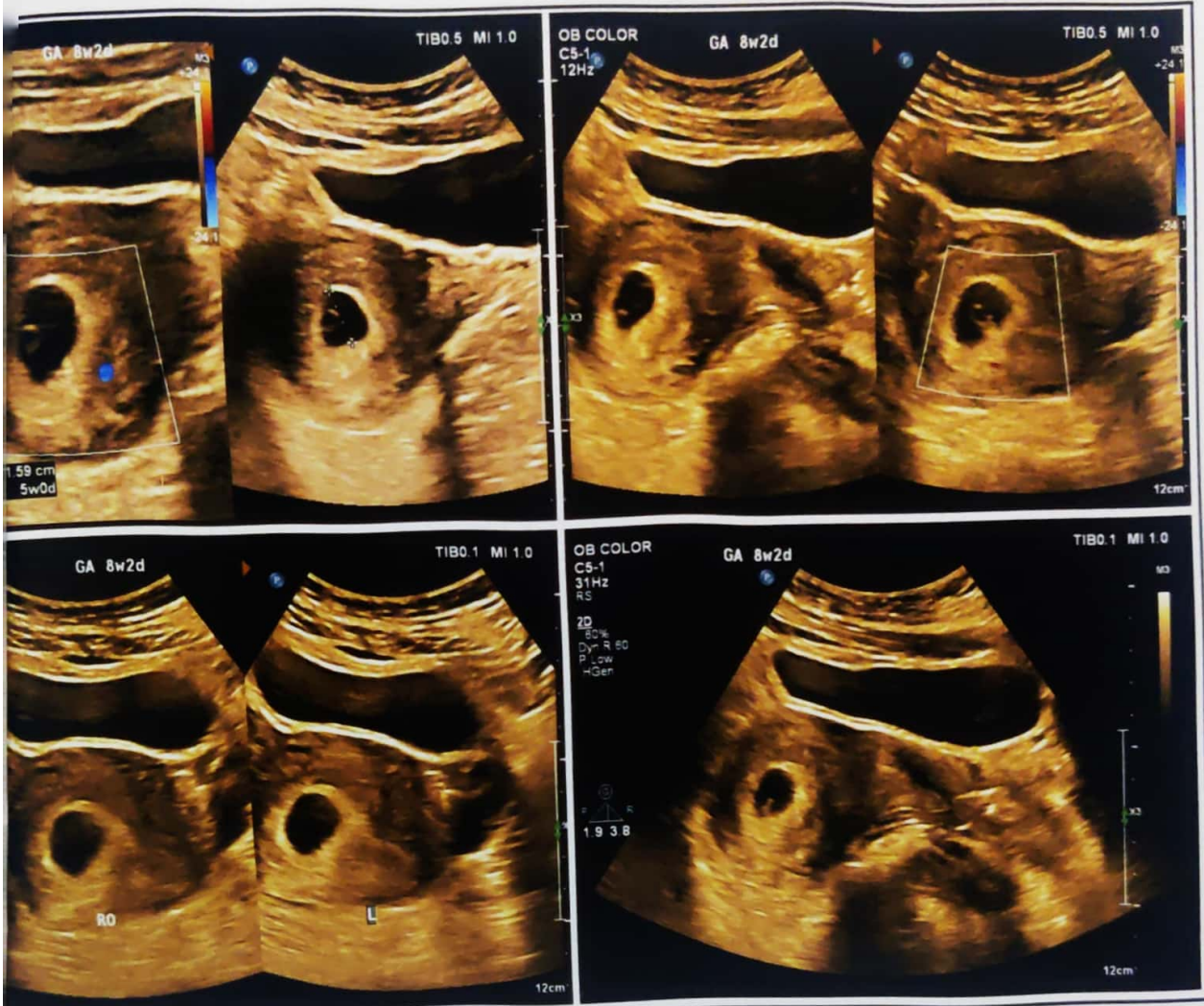

Dr. Syeda Nurjahan Begum.
MBBS. MD.
Consultant Radiologist (IBN SINA).

Prepared by "Ria"

10/8)
10/8)
6/8)
Suresh

Study Date: 06/09/2022

471211



Signature

Signature:

Name(Print):

Date:

AKILA

B471211

06/09/2022

Created: 10:43AM 06/09/2022

1/1

ডাঃ ফারহানা বিনতে রশিদ

এমবিবিএস, এফসিপিএস (গাইনী এন্ড অবস), বিসিএস (স্বাস্থ্য)
প্রসূতী, স্ত্রী রোগ বিশেষজ্ঞ ও সার্জন
কনসালটেন্ট
ঢাকা মেডিকেল কলেজ হাসপাতাল, ঢাকা।

Blighted
ovum

Dr. Farhana Binty Rashid

MBBS, FCPS (Gynae & Obs), BCS (Health)
Gynae & Obs Specialist & Surgeon
Consultant
Dhaka Medical College Hospital, Dhaka
BMDC Reg. No. : A 34784

Name : Mrs. Akila Raza

Age : 25 yrs Date : 04/10/22

MMKil due to
Blighted ovum
passage of clot
& pain on 1/10/22

Rx

- Tab. Cytomis 200 mg
১ টি ট্যাব এক সাথে খাওন - ১ দিন
- Tab. Neofloxin 500mg ২+০+০ - ৭ দিন
- Tab. FAMXD 500mg ১+০+০ - ৭ দিন
- Tab. Visceral ১+০+০ - তিনবারে
৭খা ২দিন খাও
- Cap. Progut 20mg ১+০+০ - ৭ দিন

Adv

usage of LA - ১৪ দিন

Rmv
04/10/22

বিঃ দ্রঃ পরবর্তী ভিজিটের সময় এই ব্যবস্থাপত্রটি সঙ্গে নিয়ে আসবেন।



চেয়ার : ইবনে সিনা ডায়াগনোস্টিক এন্ড কনসালটেশন সেন্টার, বাড্ডা, বাড়ি নং- ৮-৭২/১, প্রগতি স্বরণী, উত্তর বাড্ডা, ঢাকা-১২১২।
রোগী দেখার সময় : শনি থেকে বৃহস্পতিবার সন্ধ্যা ৬.০০টা থেকে রাত ৮.৩০টা (মঙ্গল ও শুক্রবার বন্ধ)

সিরিয়ালের জন্য : ০৯৬১০০০৯৬১৪

Doctors Appointment Apps link : <http://shorturl.at/dyzK0>

ডাঃ ফারহানা বিনতে রশিদ

এমবিবিএস, এফসিপিএস (গাইনী এন্ড অবস), বিসিএস (স্বাস্থ্য)
 প্রসূতী, স্ত্রী রোগ বিশেষজ্ঞ ও সার্জন
 কনসালটেন্ট
 ঢাকা মেডিকেল কলেজ হাসপাতাল, ঢাকা।

OTVR

Dr. Farhana Binty Rashid

MBBS, FCPS (Gynae & Obs), BCS (Health)
 Gynae & Obs Specialist & Surgeon
 Consultant
 Dhaka Medical College Hospital, Dhaka
 BMDC Reg. No. : A 34784

Name: Mrs. Akila Raisa

Age: 25 yrs Date: 04/09/22

Preg 7 wks

Home PT +ve

No complaints

C-Regulor

AP - 10/07/22

AD - 14/04/23

Rimip

SH - 10

→ 2.5 doses

100/65 mmHg

59.2kg

Rx

• Tab. Folic-2 0+0+0 → ৩মাস

• Cap. EXIUM mups ১+০+০ → ১মাস

ADD

• CBC

• Bl. groupin

• FBS

Bl. sugar 2HA 75 gm glucose

• STBS by screen test

• VDRL

• urine R/E.

• USA of LIA.

[Signature]
 04/09/22

বিঃ দ্রঃ পরবর্তী ভিজিটের সময় এই ব্যবস্থাপত্রটি সঙ্গে নিয়ে আসবেন।



চেখার : ইবনে সিনা ডায়াগনোস্টিক এন্ড কনসালটেশন সেন্টার, বাজ্জা, বাড়ি নং- ৮-৭২/১, প্রগতি স্বরণী, উত্তর বাজ্জা, ঢাকা-১২১২।

রোগী দেখার সময় : শনি থেকে বৃহস্পতিবার সন্ধ্যা ৬.০০টা থেকে রাত ৮.৩০টা (মঙ্গল ও শুক্রবার বন্ধ)

সিরিয়ালের জন্য : ০৯৬১০০০৯৬১৪

Doctors Appointment Apps link : <http://shorturl.at/dyzK0>

TSH on 6/6/22 → 2.51 uIU/ml

5th wk
USA - NO foetal pole

ON 07/19/22

Adv

USA of L/A - ~~29/09/22~~

ON 29/09/22

R

~~Keep~~
palpitation

→
Brighter over

• To MM kit

ନିର୍ଦ୍ଦିଷ୍ଟ କର ରଖନ୍ତୁ ।

• Tab. FLAMEX 400m (500 ମାଟ) 2+0+0 - ~~କମ୍ପାଣୀ~~ ~~29/09/22~~

• Tab. nival 2+0+0 - ~~କମ୍ପାଣୀ~~ ~~29/09/22~~

• Cap. Proquil 200m 2+0+0 → 9 ମିନି .

ULTRASONOGRAM REPORT

I.D. No : B511973 Received date : 22 Oct 2022 Printed date: 22 Oct 2022 11:03AM
Name of Pt. : AKILA RAISA Age : 25 y(s) Sex: Female
Referred by : DR. FARHANA BINTY RASHID. MBBS. FCPS.
Part Scanned: USG LOWER ABDOMEN 4D

Thank you for the courtesy of this kind referral

URINARY BLADDER

: Urinary bladder is well filled. Wall thickness appears normal. No intravesical lesion is seen.

UTERUS

: Uterus is normal in size (Tr- 4.05 x L- 8.32 X AP- 3.55) cm and anteverted in position. Myometrium shows uniform echotexture all over. Endometrial echo is centrally placed. **Endometrial cavity is empty, no any retained product of conception is seen within.**

ADNEXA


: Both adnexal regions appear normal. (Volume of RO – 3.9 cc & LO – 3.8 cc). No adnexal mass or any cystic lesion is seen.

CUL-DE-SAC

: No collection is seen.

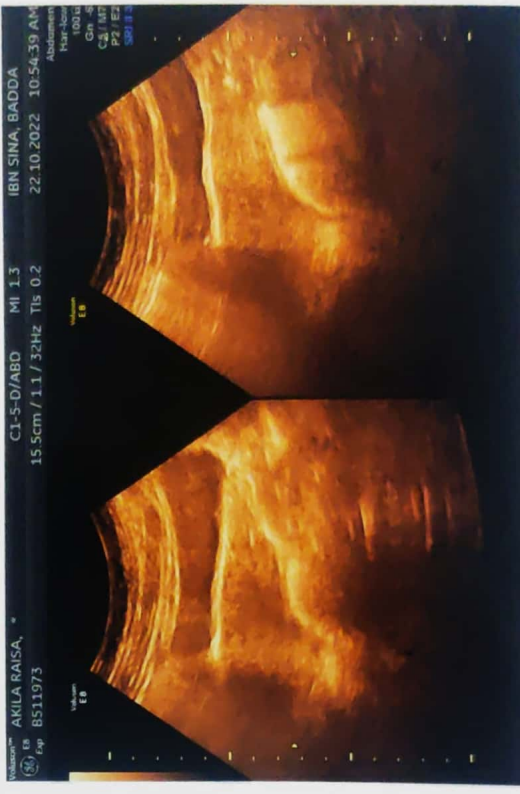
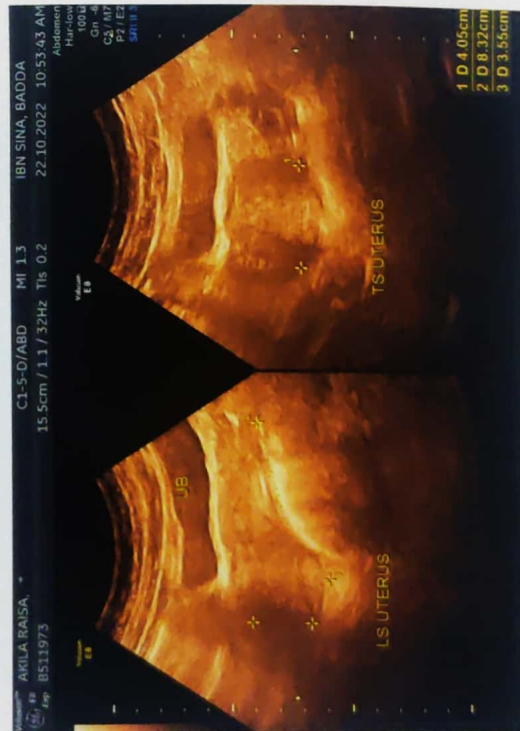
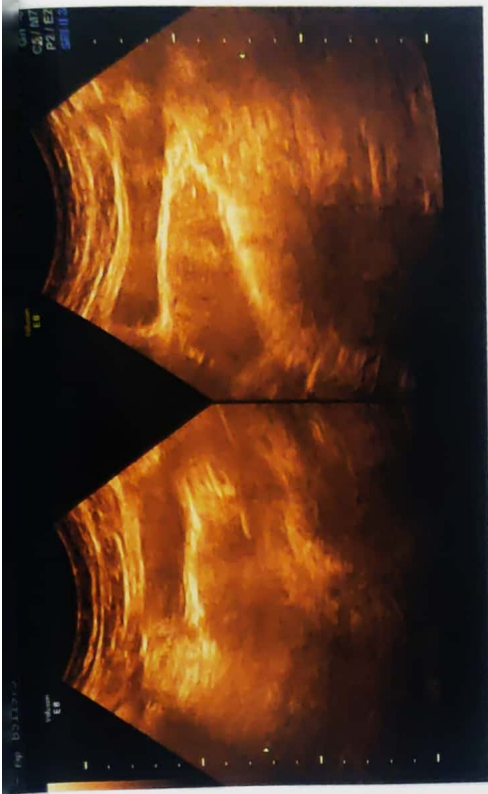
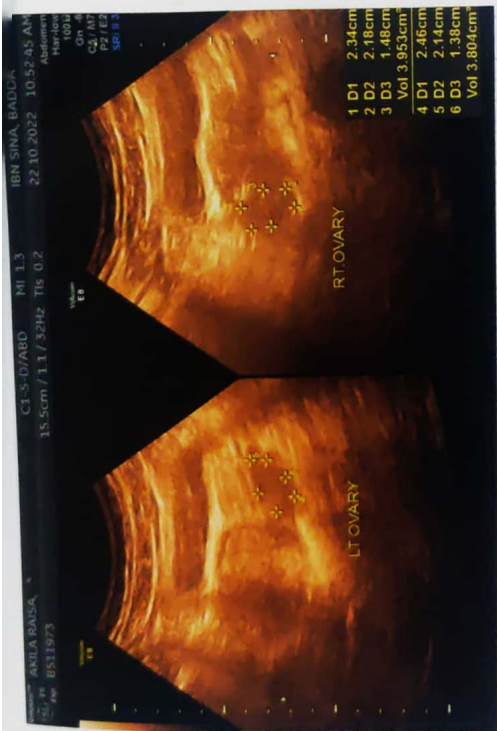
IMPRESSION

: Normal sonographic study.


Dr. Nusrat Jahan.
MBBS (Dhaka)
M-Phil (Radiology & Imaging).
Dhaka Medical College Hospital.
Consultant Radiologist (IBN SINA).
Ex-Assistant Professor, TMMCH
BMDC Reg No- A 31665

Prepared by Mariam

***Please bring all previous records including ultrasound reports in next scan.





SQUARE Hospitals Ltd

18/F, Bir Uttam Qazi Nuruzzaman Sarak,
Panthapath, Dhaka-1205.

Department of Radiology

VN : 2209225431

HN : 2209010045

Name : AKILA RAISA

Age : 24 Y 0 M 23 D

Gender : F

CN :

Exam Date : 27/09/2022

Ref By : DR. FARHANA BINTY RASHID

HN



ACCESSION NO



22090217237

VN



USG PELVIS TRANSVAGINAL (TVS) 2D

Clinical Information:

H/O 11+ weeks amenorrhoea.

Findings:

Both TAS & TVS Done:

Gravid uterus contains single slightly elongated shape gestational sac with yolk sac.

No fetal pole or fetal cardiac pulsation could be visualized.

MSD - 32.9 mm, which corresponds to 8 weeks of gestation.

No retro sac collection is noted.

CERVIX: Normal in size. Internal os is closed.

RIGHT OVARY : Normal in size (volume - 4.54 cm³). Ovarian parenchyma shows normal echogenicity with regular outline.

LEFT OVARY : Normal in size (volume - 4.72 cm³). Ovarian parenchyma shows normal echogenicity with regular outline.

CUL-DE-SAC : No fluid collection is noted.

Impression :

* Intrauterine pregnancy of about 8 weeks, with yolk sac and no detectable fetal pole - Possibly Blighted ovum.

6/9-5
27/-

10/7) -4
10/8) u
10/9) 3+

11P

Report performed by: (Electronic Signature)

Finalized By : Dr. Lutfun Nahar, Sonologist, MBBS, DMUD, Adv. Training on Doppler, Vascular & TVS

Transcribed By : Razia Sultana, Transcriptionist - Radiology & Imaging,

