

Prof. (Dr.) A H M Rowshon

MBBS, FCPS (Med.), MD (Gastro)
Commonwealth Fellow-gastro (UK)
Professor of Gastroenterology
Dept. of GHPD, BIRDEM, Shahbag, Dhaka
Ex. Professor & Head of Gastroenterology
Shaheed Suhrawardy Medical College & Hospital, Dhaka
Liver, Gastrointestinal & Medicine Specialist

21 JUN 2022

537P

MS Happy Das

Pabu
Santus
Borhug

119/77

Ep1

Bham Stoy

D

Ans: 996⁰ aap
TCL H Ep 5

Endoscopy

concl

Antral
ulcer to depth
→ possibly
different
cancer

Tab DELANZO (30)

20 or 2

in 2 mg
to 100

Syp UCRA PATE

2 x 2 L RAN

20/21

27 JUN 2022

Tab. BINOCULAR (500)

20 or 2 - 28/21

= 9 = MOTACIL (500)

20 or 2 - 28/21

Adv.

To consult a SURGEON

16 JUL 2022

Refd to

Prof. Kamruzzaman Chowdhury

Oncologist

Professor of Oncology

Bangladesh Specialized
Hospital.

per N/A please

16/07/22

Request for Investigations

Name : Ms Happy Age : 25 Sex : F

- CBC, TCDC Hb, ESR, PBF, Pi-count
- S. Bilirubin
- SGPT
- SGOT
- S Alkaline Phosphatase
- Prothrombin Time
- S. Albumin
- S. Globulin, A:G
- Gamma GT
- HBs Ag
- HBe Ag
- HBV- DNA Quantitative (PCR method)
- Anti HBe- Antibody titre / Anti HBs - Antibody
- Anti HBc / IgM / IgG / total
- Anti-HEV IgM
- Anti-HAV IgM
- Anti-HCV
- Serum Copper level
- S. Ceruloplasmin
- S. Ferritin Level
- S. Total iron level
- Blood glucose-FBS/2HA7GGI/2HABF/Random
- S.T.I.B.C
- T3. T4. TSH, FT4
- IgA t TTG
- Anti-gliadin Antibody
- Anti-microsomal antibody
- Urine for RME & C/S
- Urine for Copper level
- Stool for RE & C/S
- Stool for Blood / Haemoglobin / OBT
- CXR
- X-ray of Cervical / Thoracic / Lumber Spine
- B. Urea
- S. Creatinin
- Lipid Profile
- S. Electrolytes
- Others

21 JUN 2022

[Handwritten signature]

[Handwritten notes]
← Happy 19 CRP Anty Tg

- X-ray Pelvis SI View
- Plain X-ray Abdomen, including domes of diaphragm
- USG for Whole abdomen / BBS / Pancreas / KUB
- Ba-meal X-ray & Stomach & duodenun
- Ba-meal X-ray & follow through
- B-Swallow Oesophagus
- Ba-enema D/C
- Endoscopy of upper GIT
- EVL (Esophageal Vericeal Ligation)
- ERCP
- Colonoscopy Full / Short
- Procto-Sigmoidoscopy
- Polypectomy - Endoscopic /
Colonoscopic / Sigmoidoscopic
- CT Scan- Whole/Upper/Lower Abdomen/ HBS/ Head/
Cervical/ Lumbo- Sacral spine

বিকার ৪টায় খালিপেটে (সকালে নাস্তার পরে
পরীক্ষা না হওয়া পর্যন্ত আর কিছু খাবেন না)

পরীক্ষার আগের রাতে Duralax ২টা
খাবেন, পরীক্ষার দিন সকালে নাস্তা করে ৯ টায়
আসবেন

ফোন-৫
নভেদা ফার্মার
৪র্থ তলা
৪১৬নং ২...

২৫/০০/২

Prof. A H M Rowshon
MBBS, FCPS, MD
Professor of Gastroenterology



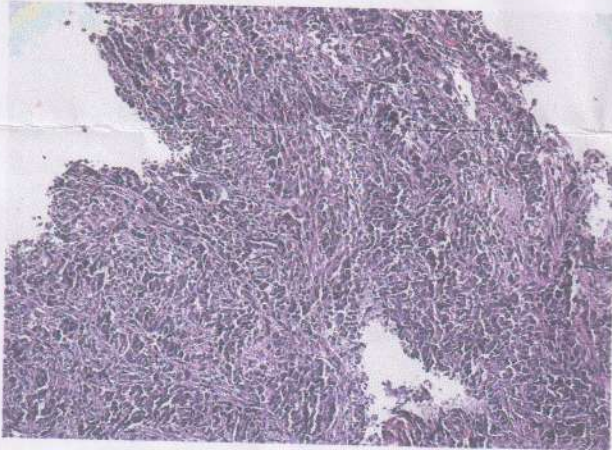
Center for Diagnosis and Cancer Research

ANOWARA MEDICAL SERVICES

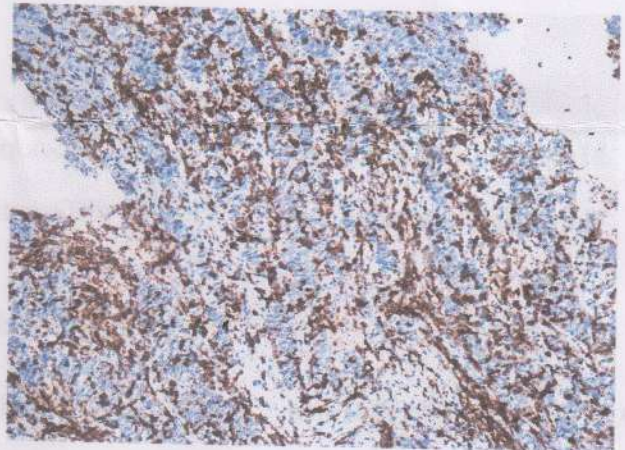
Hosue # 22/A, Road # 2, Dhanmondi Residential Area
Dhaka-1205, Bangladesh. Phone: 01971534317, 01971534318

IMMUNOCYTO-HISTOCHEMISTRY REPORT

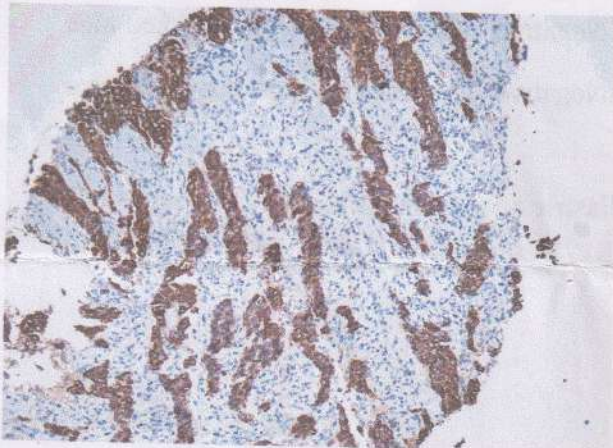
Patient's Name : Ms. Happy	Patient's ID : 000000779507
Age : 25 Year(s) Sex : Female	Case ID : 220000035023
Referred by : Prof. AHM Rowshan MBBS, FCPS, MD Gastro	Lab No : 22-022-2380
Specimen : Paraffin block prepared from gastric antral tissue	Exam : 08 Jul 2022
Investigation : Immunocyto-histochemistry	



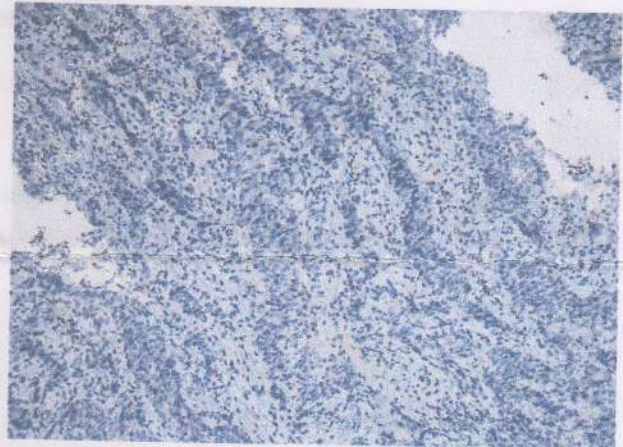
H&E; Poorly differentiated carcinoma.



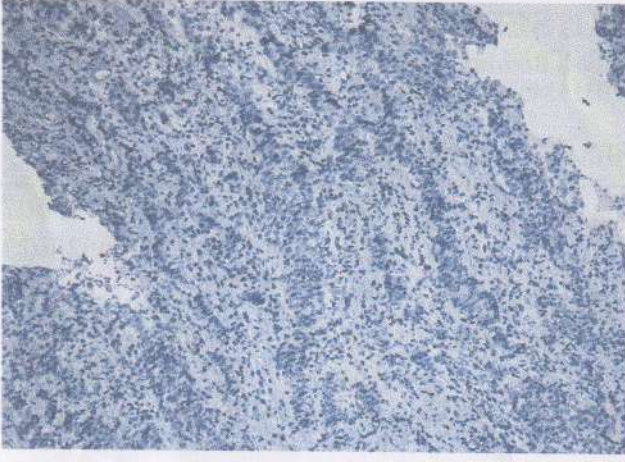
LCA



Cytokeratin



CK7



CK20



Her-2

- Material submitted** : Paraffin block prepared from gastric antral tissue.
- Working diagnosis** : Poorly differentiated carcinoma.
- LCA/CD-45** : The large binucleated cells are Negative but the background cells are positive.
- Cytokeratin/Pankeratin** : The tumour cells are Positive. The external control worked nice.
- Her-2 (c-erbB-2 oncoprotein)** : Weak Positive (Score 1+: Less than 10% tumour cells show incomplete membrane staining)
External Control: Satisfactory and Stained perfectly.
According to 2013 CAP guideline.
- CK 20** : The tumour cells are Negative. The external control worked nice.
- CK 7** : The tumour cells are Negative. The external control worked nice.
- Impression** : Her 2/neu Negative Gastric adenocarcinoma.

With Compliments for kind referral

(Dr. Mohammad Golam Mostafa)
MBBS, M Phil Pathology (Honors)
WHO Fellow in Cytopathology, Bangkok
Ex Professor of Histopathology
National Institute of Cancer Research and Hospital
E-mail: anowarams@gmail.com

আনোয়ারা মেডিকেল সার্ভিসেস
বাসা নং-২২এ, রাস্তা নং-২,
ধানমন্ডি আবাসিক এলাকা, ঢাকা
ফোন: ৯৬১১৮০১, ৯৬১২৩৩৭

রোগীর অন্য রিপোর্ট/অবস্থার সাথে অঙ্গিল হলে ২১ দিনের ভিতর এলে রিপোর্ট রিভিউ করে দেয়া হবে।



পপুলার ডায়াগনস্টিক সেন্টার লিঃ POPULAR DIAGNOSTIC CENTRE LTD.

POPULAR

Head Office : House # 16, Road # 2, Dhanmondi R/A, Dhaka-1205
HOTLINE : 09613 787801, 09666787801, E-mail : info@popularidiagnostic.com, Web : www.popularidiagnostic.com

LABORATORY SERVICES

Patient Name	Ms. Happy	Lab No	2150846
UHID	11199284	Sample Collection Date	21/06/2022 10:02PM
Age/Gender	25 Yrs/Female	Receiving Date	21/06/2022 11:56PM
Referred By	Prof. Dr. A H M Rowshon, MBBS, FCPS(Med), MD(Gastro)	Report Date	22/06/2022 8:52AM
		Report Status	Final



Test Name	Result	Unit	Reference Range
-----------	--------	------	-----------------

HAEMATOLOGY REPORT

CBC, ESR

Sample: WHOLE BLOOD

Total Count

White Blood Cells	8.96	K / μ L	4.00 - 10.00
Neutrophils	6.00	K / μ L	2.00 - 7.00
Lymphocyte	2.60	K / μ L	1.00 - 3.00
Monocyte	0.27	K / μ L	0.20 - 1.00
Eosinophil	0.09	K / μ L	0.02 - 0.50

Differential Leucocyte Count

Neutrophil%	67	%	40.00 - 80.00
Lymphocyte%	29	%	20.00 - 40.00
Monocyte%	03	%	2.00 - 10.00
Eosinophil%	01	%	1.00 - 6.00
Basophil%	00	%	<1-2
Red Blood Cells	3.87	million/ μ l	3.80 - 4.80
Haemoglobin	9.90	g/dL	12.00 - 15.00
HCT	32.30	%	34.80 - 45.00
MCV	83.5	fl	79 - 96
MCH	25.6	pg	26 - 33
MCHC	30.7	g/dL	32 - 36
RDW-CV(%)	16.5	%	11 - 15
Platelets	520	K / μ L	150 - 410
MPV	9.30	fl	8.00 - 11.00
PCT	0.49	%	0.13 - 0.40
PDW	9.00	fl	8.30 - 15.90
ESR	51	mm/hr	0 - 12


Prof. Md Jamshed Haider Siddique
MBBS, M.Phil (Path) Professor of Pathology,
Head, Department of Pathology.



পপুলার ডায়াগনস্টিক সেন্টার লিঃ POPULAR DIAGNOSTIC CENTRE LTD.

Head Office : House # 16, Road # 2, Dhanmondi R/A, Dhaka-1205
HOTLINE : 09613 787801, 09666787801, E-mail : info@populardiagnostic.com, Web : www.populardiagnostic.com

LABORATORY SERVICES

Patient Name	Ms. Happy	Lab No	2150847	
UHID	11199284	Sample Collection Date	21/06/2022 10:03PM	
Age/Gender	25 Yrs/Female	Receiving Date	23/06/2022 12:02PM	
Referred By	PROF. DR. AHM ROWSHON, MBBS, FCPS (MED), MD (GASTRO)	Report Date	23/06/2022 12:34PM	
		Report Status	Final	

Test Name	Result	Unit	Reference Range
-----------	--------	------	-----------------

IMMUNOLOGY REPORT

ICT for COVID-19 Antigen
(Rapid Test)

Negative

Sample: Nasal Swab

Note: This is a screening test. Please confirm the test by
COVID-19 Real Time RT-PCR method.



Mohammad Intajur Rahman
B.S. (Hon's), M.S.(B.M.B),DU
Molecular Biologist
Popular Diagnostic Center Ltd.



Center for Diagnosis and Cancer Research

ANOWARA MEDICAL SERVICES

Hosue # 22/A, Road # 2, Dhanmondi Residential Area
Dhaka-1205, Bangladesh. Phone: 01971534317, 01971534318

HISTOPATHOLOGY REPORT

Patient's Name : Ms. Happy	Patient's ID : 000000779507
Age : 25 Year(s) Sex : Female	Case ID : 220000034204
Referred By : Prof. AHM Rowshan MBBS, FCPS, MD Gastro	Lab No : 22-001-13746
Specimen : Gastric antral tissue	Exam Date : 25 Jun 2022
Investigation : Histopathology	

Macroscopic Description

Specimen received in formalin with proper lab no with patient's identification consists of three tiny grey white pieces of tissue. The largest one measures about 0.3 cm. Embedded as such.

Microscopic Description

Sections show a malignant tumour made of monotonous population of cells having large pleomorphic nucleoli. These cells are arranged in sheets and nests. The surface is ulcerated.


Dx

Gastric antral tissue (endoscopic biopsy) : Poorly differentiated carcinoma.

Remarks

Immunohistochemistry is recommended for confirmation (A4).

With Compliments for kind referral


(Dr. Mohammad Golam Mostafa)

MBBS, M Phil Pathology (Honors)
WHO Fellow in Cytopathology, Bangkok
Ex Professor of Histopathology
National Institute of Cancer Research and Hospital
E-mail: anowarams@gmail.com

আনোয়ারা মেডিকেল সার্ভিসেস
বাসা নং-২২এ, রাস্তা নং-২,
ধানমন্ডী আবাসিক এলাকা, ঢাকা
ফোন: ৯৬১১৮০১, ৯৬১২৩৩৭

রোগীর অন্য রিপোর্ট/অবস্থার সাথে অমিল হলে ২১ দিনের ভিতর এলে রিপোর্ট রিভিউ করে দেয়া হবে।

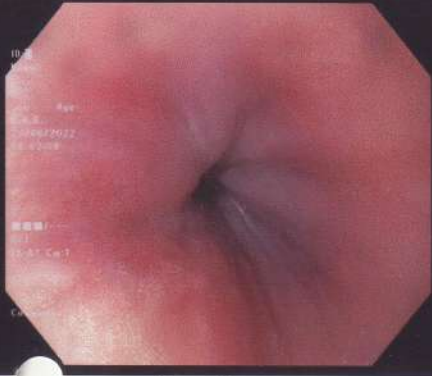


পপুলার ডায়াগনস্টিক সেন্টার লিঃ POPULAR DIAGNOSTIC CENTRE LTD.

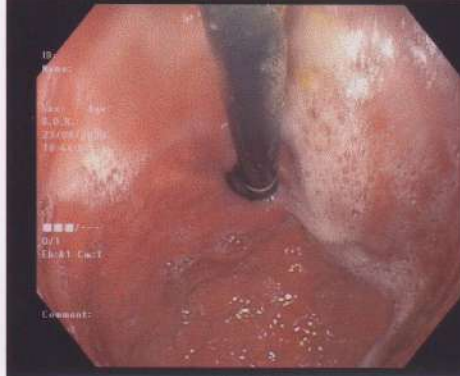
POPULAR Head Office : Unit-2, House # 5, Road # 2, Dhanmondi, Dhaka. Tel : 9669480-89, Fax : 9666804, E-mail : popular@popularbd.com

Identity No.	466	MRN	D 11199284	Visit Date	6/23/2022
Patient Name	Ms. Happy	Bed		Age/Sex	25 / Female
Referrer	Prof. Dr. A.H.M. Rowshon MBBS,FCPS.			Instrument	OLYMPUS CV-170

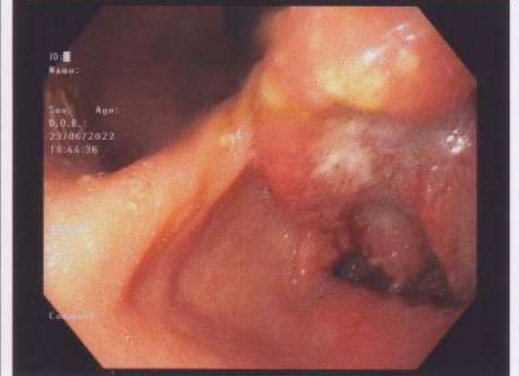
ENDOSCOPIC PROCEDURE REPORT



Oesophagus



Fundus



Antrum

Procedure : Video Endoscopy of Upper GIT.

Indication : N/A

Medication : N/A

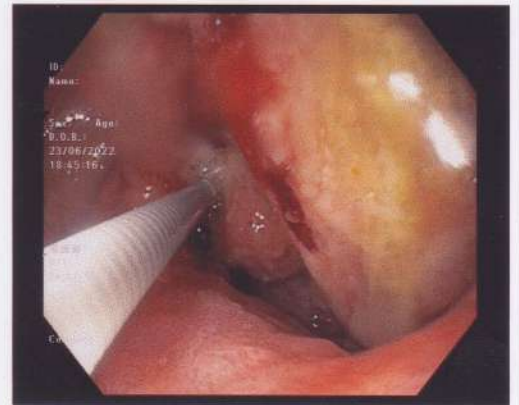
FINDINGS :

•**Oesophagus:-** Normal.

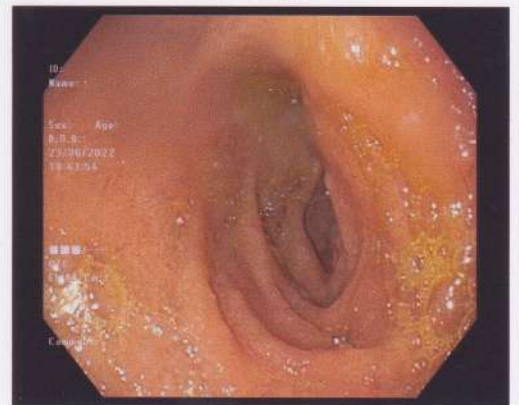
•**Stomach:-** A proliferative ulcerated growth (?) is seen in the antrum near the pyloric opening. Rest of the areas are normal.

•**Duodenum:-** Bulb and post bulbar areas are normal.

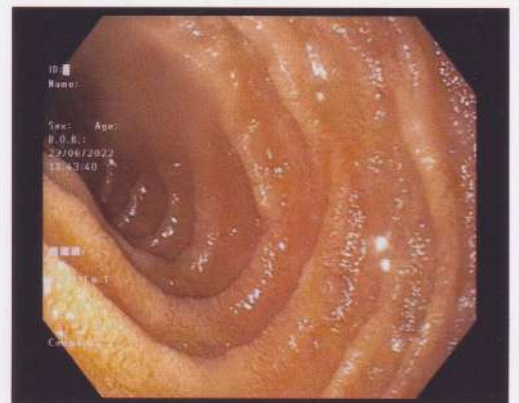
Biopsy:- Taken.



Antrum



Bulb



D2

COMMENTS : Antral ulcerated growth.

Prof. A.H.M. Rowshon

MBBS, FCPS, MD (Gastro)

Professor of Gastroenterology

Shaheed Suhrawardy Medical College & Hospital, Dhaka