



evercare

HOSPITAL CHATTOGRAM
Transforming Healthcare

Plot # H1, Ananna Residential Area, CDA, Oxygen-Kuwaish Road, Chattogram, Bangladesh, T +880241380350-61
infoctg@evercarebd.com, www.evercarebd.com
Appointments & Emergency Care 10663

INVESTIGATION REPORT



Lab No/Manual No : 97849 / BG22112889

Order No. : OP23/67910

Patient Name : . ZANNATUL FERDAUS

UHID : 5048716

Age/Gender : 19 Yrs/Female

Sample Collected : 10/11/2022 01:07PM

Referred By : Dr. MD SURMAN ALI

Sample Received : 10/11/2022 02:03PM

Clinical History :

Report Date : 12/11/2022 10:27AM

Bed No/Ward : OPD

Report Status : Finalized

HAEMATOLOGY

Test Name	Result	Unit	Reference Range	Method
CBC				
Sample: Whole Blood				
Red Blood Cells				
HB (HEMOGLOBIN)	11.4	gm/dl	11.5 - 16.5	Flowcytometry.
RBC Count	3.87	10 ¹² /L	3.80 - 5.50	Carried out by sysmex XN-2000 series.
PCV [PACKED CELL VOLUME]	33.20	%	36.00 - 48.00	
MCV	85.80	fl	83.00 - 101.00	
MCH	29.50	pg	27.00 - 32.00	
MCHC	34.30	%	31.50 - 34.50	
RDW-SD	39.20	fl	39.00 - 46.00	
RDW-CV	12.20	%	11.60 - 14.00	
WBC Count	16.98	10 ⁹ /L	4.00 - 11.00	
Differential Counts				
Neutrophils	92.20	%	40.00 - 80.00	
Lymphocytes	5.20	%	20.00 - 40.00	
Monocytes	2.40	%	2.00 - 8.00	
Eosinophils	0.10	%	1.00 - 6.00	
Absolute Values				
Absolute Neutrophils Count	15.67	10 ⁹ /L	2.00 - 7.00	
Absolute Lymphocytes Count	0.89	10 ⁹ /L	1.00 - 3.00	
Absolute Monocytes Count	0.40	10 ⁹ /L	0.20 - 1.00	
Absolute Eosinophils Count	0.01	10 ⁹ /L	0.02 - 0.50	
PLATELET COUNT	295	10 ⁹ /L	150 - 400	
MPV	10.80	fl	9.00 - 12.00	
PCT	0.32	%	0.22 - 0.40	
PDW	12.60	fl	9.80 - 16.00	

End of Report

SUDIPTA SAHA

Medical Technologist- Haematology

Prepared By: MOHAMMAD MAMUN

Printed By: 50701

Dr. SHAMIM ARA BEGUM

MBBS, M.Phil (Clinical Pathology) FCPS (Hematology),
Associate Consultant-Hematology & Clinical Path

Printed at 14/11/2022 12:09 Page: 4 Of 4



evercare

HOSPITAL CHATTOGRAM
Transforming Healthcare

Plot # H1, Ananna Residential Area, CDA, Oxygen-Kuwaish Road, Chattogram, Bangladesh, T +880241380350-61
infoctg@evercarebd.com, www.evercarebd.com
Appointments & Emergency Care 10663

INVESTIGATION REPORT



Lab No/Manual No :	97849 / BG22112889	Order No.	: OP23/67910
Patient Name	: ZANNATUL FERDAUS	UHID	: 5048716
Age/Gender	: 19 Yrs/Female	Sample Collected	: 10/11/2022 05:08PM
Referred By	: Dr. MD SURMAN ALI	Sample Received	: 10/11/2022 07:47PM
Clinical History	:	Report Date	: 12/11/2022 10:37AM
Bed No/Ward	: OPD	Report Status	: Finalized

CLINICAL PATHOLOGY

URINE PROFILE

Sample: Urine

Physical Examination

Colour	Light Yellow
Appearance	Clear
Sediment	Nil

Chemical Examination

Specific Gravity	>=1.030	1.005-1.030
Reaction (PH)	6.0	5.0-8.0
Protein	++	
Sugar	Nil	
Micro albumin	Present	
Nitrite	Nil	
Urine Bilirubin	Absent	
Urobilinogen	Normal	
Absorbic Acid	Absent	

Microscopic Examination

Pus Cells	20-30	/HPF
RBCs	8-10	/HPF
Yeast Cells	++	/HPF
Epithelial Cells	25-30	/HPF

Crystal

Uric acid	Nil	/HPF
Calcium Oxalate	Nil	/HPF
Triple Phosphate	Nil	/HPF
Amorphos Phosphate	Nil	/HPF

Casts

Granular Casts	Nil	/LPF
Hyaline Casts	Nil	/LPF
WBC Casts	Nil	/LPF
RBC Casts	Nil	/LPF

End of Report

SUDIPTA SAHA

Medical Technologist- Haematology

Prepared By: MOHAMMAD MAMUN

Printed By: 50701

Dr. SHAMIM ARA BEGUM

MBBS, M.Phil (Clinical Pathology) FCPS (Hematology),

Associate Consultant-Hematology & Clinical Path

Printed at 14/11/2022 12:09

Page: 2 Of 4



evercare

HOSPITAL CHATTOGRAM
Transforming Healthcare

Plot # H1, Ananna Residential Area, CDA, Oxygen-Kuwaish Road, Chattogram, Bangladesh, T +880241380350-61
infoctg@evercarebd.com, www.evercarebd.com
Appointments & Emergency Care 10663



INVESTIGATION REPORT

Lab No/Manual No : 97849 / BG22112889	Order No. : OP23/67910
Patient Name : ZANNATUL FERDAUS	UHID : 5048716
Age/Gender : 19 Yrs/Female	Sample Collected : 10/11/2022 01:07PM
Referred By : Dr. MD SURMAN ALI	Sample Received : 10/11/2022 02:25PM
Clinical History :	Report Date : 10/11/2022 03:09PM
Bed No/Ward : OPD	Report Status : Finalized

BIOCHEMISTRY

Test Name	Result	Unit	Reference Range	Method
CREATININE	0.85	mg/dl	0.50 - 1.20	Modified Alkaline Picrate (Rate Jaffe) Sample: Serum
HB A1C	5.3	%	Non-Diabetic : Up to 5.6 Pre-Diabetic : 5.7 - 6.4 Diabetic : >6.5 Good Control : Up to 7 Fair Control : 7.1 - 8.0 Sub - Optimal Control : 8.1 - 10.0 Poor Control : > 10.0 Sample: Whole Blood	HPLC
GLUCOSE (Random)	5.0	m mol/L	Normal : <7.8 Impaired : 7.8 - 11.1 Diabetic : >11.1 Sample: Plasma	Hexokinase

End of Report

SHUVA CHAKRABORTY

Medical Technologist

Prepared By: MOHAMMAD MAMUN

Printed By: 50701

PROF DR MAHMUDUL HAQUE

MBBS, MPhil

Sr. Consultant - Biochemistry & Molecular Biology

Printed at 14/11/2022 12:09

Page: 1 Of 4



evercare

HOSPITAL CHATTOGRAM
Transforming Healthcare

Plot # H1, Ananna Residential Area, CDA, Oxygen-Kuwaish Road, Chattogram, Bangladesh, T +880241380350-61
infoctg@evercarebd.com, www.evercarebd.com
Appointments & Emergency Care 10663

INVESTIGATION REPORT

Lab/Manual No	: 97882	Order No	: OP23/68062
Patient Name	: ZANNATUL FERDAUS	UHID	: 5048716
Age/Gender	: 19 Y/F	Sample Collected	: 10/11/2022 3:30PM
Referred By	: Dr. MD SURMAN ALI	Sample Received	: 10/11/2022 4:09PM
Ward/Bed No	: OPD	Report Date	: 13/11/2022 4:02PM
Clinical History	:	Report Status	: Finalized

CT SCAN

ANGIO NECK VESSELS (CT SCAN)

Brief Clinical Notes: H/O swelling in right side of neck for 7 years. Previous H/O twice operation.

Techniques: CT Angiography of neck vessels performed using non-ionic contrast with bolus tracking techniques followed by MPR, MIP and 3D reconstructions.

Findings: (Reporting on films and PACS).

Multilocular cystic lesions are noted involving right cervico-fascial region with caudal extension up to mid level of thyroid gland. The lesions show moderate mass effect & minimal marginal septal enhancements after IV contrast administration. The lesion is located posteromedial to right sternocleidomastoid muscle.

No AVM, AVF or aneurysmal dilatation / narrowing is seen


Both carotids, internal carotid of both sides & both vertebral arteries are showing normal outline & caliber.

Impression:

- Status post operative.
- Multilocular cystic lesions – consistent with cystic hygroma.
- Unremarkable CT angiogram of neck vessels.

(Total 06 films supplied).

--- End of Report ---


Dr. AYESHA PERVEEN
Consultant - Radiology & Imaging
MBBS, MD
13-11-22



evercare

HOSPITAL CHATTOGRAM
Transforming Healthcare

Plot # H1, Ananna Residential Area, CDA, Oxygen-Kuwaish Road, Chattogram, Bangladesh, T +880241380350-61
infoctg@evercarebd.com, www.evercarebd.com
Appointments & Emergency Care 10663

INVESTIGATION REPORT

Lab/Manual No	: 97849	Order No	: OP23/67910
Patient Name	: . ZANNATUL FERDAUS	UHID	: 5048716
Age/Gender	: 19 Y/F	Sample Collected	: 10/11/2022 1:02PM
Referred By	: Dr. MD SURMAN ALI	Sample Received	: 10/11/2022 1:33PM
Ward/Bed No	: OPD	Report Date	: 10/11/2022 1:43PM
Clinical History	:	Report Status	: Result Entered

CARDIOLOGY

ECHO SCREENING

2D - M - Mode Measurements:

IVS(d) :6 mm (06-12)	LVPW(d) :9 mm (06-12)	Aorta :21 mm (20-40)
IVS(s) :9 mm (09-18)	LVPW(s) :11 mm (09-18)	LA :24 mm (20-40)
LVID(d) :38 mm (35-55)	FS :29 % (30-45)	ACS :18 mm (15-25)
LVID(s) :26 mm (20-40)	LVEF :56 % (50-85)	

REPORT SUMMARY

Situs solitus, two atria & two ventricles. AV & VA concordance

LA : Normal. Appendage clear.

LV : Normal chamber dimension & wall thickness.

RA : Normal RV : Normal

IAS : Intact IVS : Intact

All valves are normal in morphology & motion.

No intracardiac thrombus, mass or vegetation seen.

Pericardium - Normal. No effusion/ Thrombus or vegetation seen.

CONCLUSION:

- No Regional Wall Motion Abnormality Seen at Rest.
- Good LV Systolic Function (LVEF: 56%)

DR. ASIF UL ALAM
SENIOR REGISTRAR (CARDIOLOGY)

Patient Demographics

ZANNATUL FERDAUS 19YRS

Patient ID: 5048716

Study Date: 10/11/2022

Gender: F

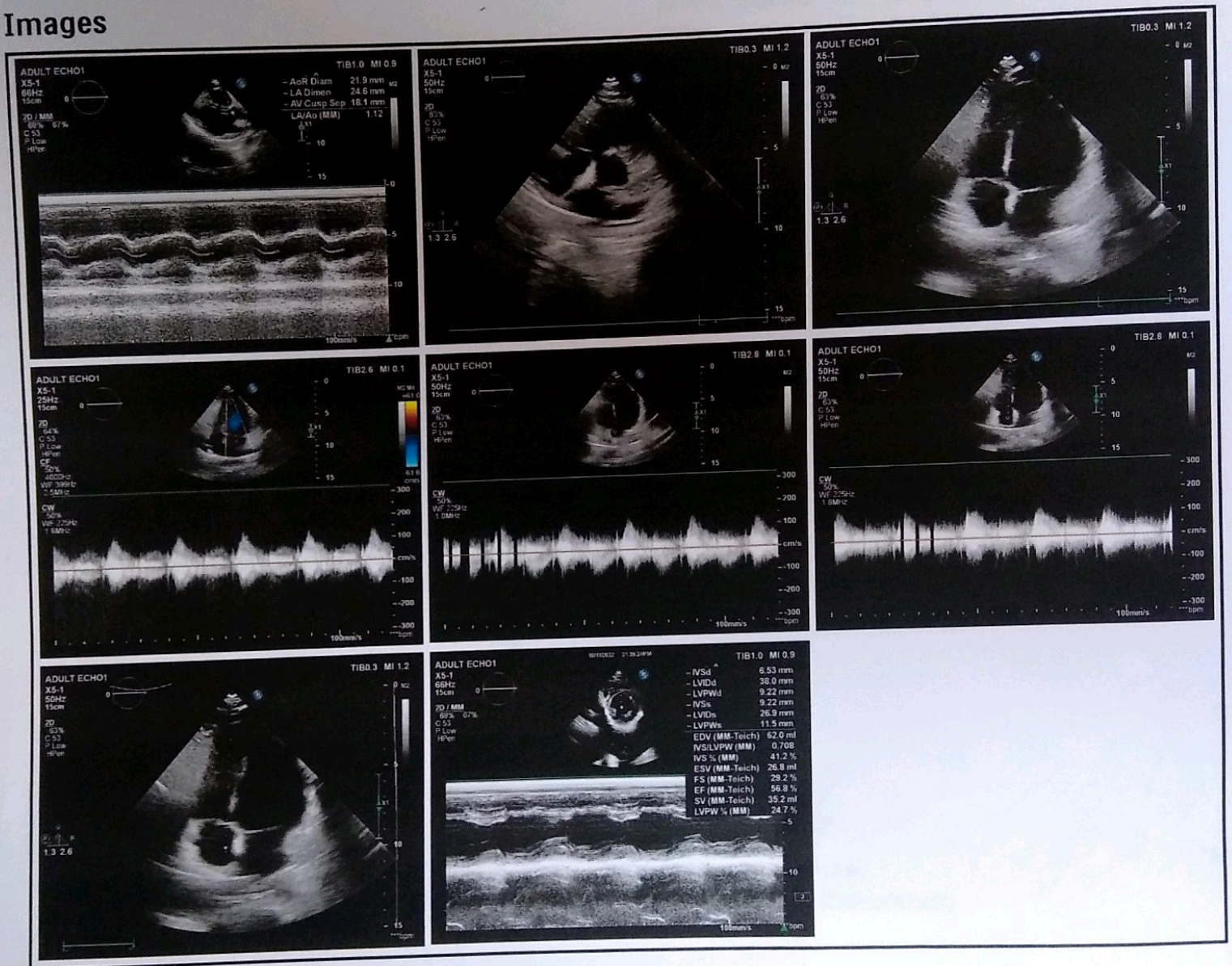
Ht:

Wt:

BSA:

Institution: Evercare Hospital Chattogram

Images



Signature

Signature:
Name(Print):

Date:



evercare

HOSPITAL CHATTOGRAM
Transforming Healthcare

Plot # H1, Ananna Residential Area, CDA, Oxygen-Kuwaish Road, Chattogram, Bangladesh, T +880241380350-61
infoctg@evercarebd.com, www.evercarebd.com
Appointments & Emergency Care 10663

INVESTIGATION REPORT

Lab/Manual No	: 97849	Order No	: OP23/67910
Patient Name	: . ZANNATUL FERDAUS	UHID	: 5048716
Age/Gender	: 19 Y/F	Sample Collected	: 10/11/2022 1:02PM
Referred By	: Dr. MD SURMAN ALI	Sample Received	: 10/11/2022 2:01PM
Ward/Bed No	: OPD	Report Date	: 12/11/2022 10:31AM
Clinical History	: To rule out any pathology	Report Status	: Finalized

X-RAY CENTER

CHEST PA(X-RAY)

Clinical data: For check-up.

Findings: (Reporting on films and PACS).

Lung fields are clear.

Basal angles are normal.

Heart is normal in size and shape.


Diaphragm is normal in position and contour.

Bony thorax revealed no abnormality.

COMMENT:

No significant radiological abnormality detected.

--- End of Report ---


Dr. AYESHA PERVEEN
Consultant - Radiology & Imaging
MBBS, MD



evercare

HOSPITAL CHATTOGRAM

Transforming Healthcare

Plot # H1, Ananna Residential Area, CDA, Oxygen-Kuwaish Road, Chattogram, Bangladesh, T +880241380350-61
infoctg@evercarebd.com, www.evercarebd.com

Appointments & Emergency Care 10663

CONSULTATION SUMMARY

UHID	: 5048716	Patient Name	: . ZANNATUL FERDAUS
Age/Sex	: Female/19 Yr 7 Mth 9 Days	Doctor name	: Dr. MD SURMAN ALI
Visit No	: Revisit	Visit Date	: 10/11/2022 12:15PM
Telephone	: 01775352836	Referred by	:
Address	: EAST CHELONIA SANUA FENI CHATTOGRAM FENI CHATTOGRAM BANGLADESH		

CHIEF COMPLAINTS

Swelling in right side of neck for 7years after 2nd operation in 2014
Pain started in the same region for 3days associated with Fever

VITALS

Date Time	Temp.	Pulse	BP	SPO2
10/11/2022 12:19 PM	97.7 F	150 /min	90/60	98 %

ALLERGIES

No Allergies.

HISTORY

1st operation 2011
2nd operation 2014

DIAGNOSIS

Recurrence cystic Hygroma of the right Neck

* Please collect your Medicine/Investigation prescription from any Billing counter.
* Now you may pay your Hospital bills and book your Doctor's appointment online. Please visit www.evercarebd.com
* Please make prior appointment for your next shedule visit. Appointment Cell Center
* Phone no: 880-2-41380350-61, 10663

Dr. MD SURMAN ALI
Senior Consultant - General Surgen
MBBS, FCP

ROUTINE ADMISSION NOTIFICATION (FORM OPD)

Date: 14.10.22 UHID: 5048716

From: _____

To: _____

Please admit Mr./Ms. : _____

Age: 19 Years: 7 Sex: M F

Type of room: _____

Provisional diagnosis: Recurrent cystic lymphoma

Procedures/Surgery Proposed: (adeno) 7418 + 5736

Please write instructions for Resident, Registrar, Nurse, Dietician on duty on reverses side.

A) Instruction to Resident/Registrar on duty :

AW
PAW DEL
RA

Dr. Md. Surman Ali
MBBS, FCPS
Sr. Consultant-General Surgery
Laparoscopic and Colorectal Surgery
Evercare Hospital Chattogram